

SIMPOSIUM FETAL SURGERY IN LATIN AMERICAN COUNTRIES

1. Fetal Medicine and Surgery Sinaloa, Mexico. ORCID 0000-0002-2709-0312
2. Fetal Medicine and Surgery Sinaloa, Mexico. ORCID 0000-0002-8950-6395
3. Director, Peruvian Institute of Fetal Medicine and Surgery, Lima, Peru. ORCID 0000-0001-6515-2599

Conflict of interest: No conflict of interest is declared.

No technology related to artificial intelligence was used in the preparation of this article.

Funding: No funding from any institution was used.

Received: February 28, 2024

Accepted: 5 March 2024

Online publication: 2 April 2024

Corresponding author:

Dr. Jairo Muñoz Acosta

📍 Calle Las Colinas 190, Lima, Perú. CP: 15023

✉️ drjairoginecologo@hotmail.com

✉️ drjairo6060923@icloud.com

Cite as: Muñoz Acosta J, Lara Ávila L, Gil Guevara E. Use of intrauterine shunts in fetal surgery. *Rev peru ginecol obstet.* 2024;79(1). DOI: <https://doi.org/10.31403/rpgo.v70i2609>

Use of intrauterine shunts in fetal surgery

Uso de derivaciones intrauterinas en cirugía fetal

Jairo Muñoz Acosta¹, Leticia Lara Ávila², Enrique Gil Guevara³

DOI: <https://doi.org/10.31403/rpgo.v70i2609>

ABSTRACT

Since the 1960s, fetal medicine has evolved rapidly. Thanks to advances in technology and the training of experts in this branch of medicine, it has become possible to make more accurate diagnoses of fetal pathologies. Most of these pathologies can be treated postnatally. However, in some cases prenatal intervention is required since otherwise the pregnancy may culminate in fetal death or serious sequelae in the newborn. Intrathoracic pathologies with mediastinal compression, aortic stenosis, lower urinary obstruction, congenital diaphragmatic hernia, myelomeningocele, lower urinary obstruction, intrauterine intravascular transfusion, fetus-fetal transfusion syndrome and TRAP sequence, among others, are the fetal pathologies susceptible to in-utero therapy. The present article refers to the use of intrauterine shunts in fetal surgery.

Key words: Fetus, Ascites, Hydrothorax, Hydrops, Pleural effusion, Urethral obstruction, Ascites, Shunt, Surgery, fetal

RESUMEN

Desde la década de 1960, la medicina fetal ha evolucionado rápidamente. Gracias a los avances de la tecnología y a la formación de expertos en esta rama de la medicina, se ha podido realizar diagnósticos más precisos de las patologías fetales. La mayoría de estas patologías pueden ser tratadas posnatalmente. Sin embargo, en algunos casos se requiere de intervención prenatal pues de lo contrario el embarazo puede culminar en muerte fetal o en graves secuelas del recién nacido. Patologías intratorácicas con compresión mediastínica, estenosis aórtica, obstrucción urinaria inferior, hernia diafragmática congénita, mielomeningocele, obstrucción urinaria inferior, transfusión intravascular intrauterina, síndrome de transfusión feto-fetal y secuencia TRAP, entre otras, son las patologías fetales susceptibles de terapia en útero. El presente artículo se refiere al uso de derivaciones intrauterinas en cirugía fetal.

Palabras clave: Feto, Ascitis, Hidrotórax, Hidropesía, Derrame pleural, Obstrucción uretral, Ascitis, Derivación, Cirugía fetal

INTRODUCTION

Since the 1960s, fetal medicine has evolved rapidly. Thanks to advances in technology and the training of experts in this branch of medicine, fetal pathologies can be diagnosed more accurately. In most cases these pathologies can be treated postnatally. However, in some cases, prenatal intervention is required, otherwise the pregnancy would result in fetal death or a newborn with severe sequelae.

In 1961, prior to the revolution in technology and the use of ultrasound, invasive procedures were performed with blind percutaneous techniques, such as the first intrauterine transfusion performed by Liley⁽¹⁾ or with an open uterus, such as the exchange transfusions performed by Adamson in 1966⁽²⁾.

Although fetal surgery is in development and undergoing much research, there are indications that justify an invasive therapeutic procedure to avoid fetal loss or a newborn with severe sequelae. Intrathoracic pathologies with mediastinal compression, aortic stenosis, low urinary obstruction, congenital diaphragmatic hernia, myelomeningocele, low urinary tract obstruction, intrauterine intravascular transfusion, fetus-fetal transfusion syndrome and TRAP sequence, among others, are the fetal pathologies susceptible to in utero therapy⁽³⁾.



Currently there are three main procedures in fetal surgery: minimally invasive fetoscopic surgery, which involves small incisions, trocar placement and surgery through the use of a fetoscope; open fetal surgery which consists of a hysterotomy to operate directly on the fetus; and percutaneous fetal treatment, which consists of placing an introducer or a needle for either laser application or placement of shunts.

In the present work a narrative review is made of the pathologies that are most frequently treated with placement of a fetal shunt in utero via percutaneous route.

FETAL LOWER URINARY TRACT OBSTRUCTION

Fetal lower urinary tract obstruction (LUTO) occurs in 1 out of every 4,000 to 8,000 pregnancies. Of these, 10% are associated with chromosomal abnormalities such as trisomies 21, 18 and 13. In addition, other structural abnormalities, mainly cardiac and gastrointestinal, are present in 40% of cases. The most frequent cause of LUTO is the posterior urethral valves. However, it can also be caused by atresia and urethral stricture⁽⁴⁾.

Involvement of the posterior urethral valves is the most common cause of chronic kidney disease in children. The exact mechanism of obstruction is not completely understood. It is known that embryonic development of the male urethra occurs between 9 and 14 weeks of gestation; a persistent obstructing urogenital membrane leads to occlusion of the membranous folds within the lumen of the posterior urethra⁽⁵⁾.

Diagnosis of this fetal pathology can be made as early as the first trimester of gestation by observing a fetal urinary bladder with a longitudinal diameter ≥ 7 mm (megabladder). In approximately 90% of cases, if the bladder diameter is 7-15 mm, there is spontaneous resolution. When the bladder diameter is ≥ 15 mm, the condition is associated with progressive obstructive uropathy leading to hydronephrosis and renal dysplasia.

Prior to the advent of fetal cystoscopy, which is still experimental, placement of a vesicoamniotic shunt has been the most common prenatal therapy for the management of LUTO. Fetuses that are candidates for this therapy are those

with isolated megabladder, no associated congenital anomaly, normal male karyotype, bilateral hydronephrosis, oligohydramnios and normal fetal uroanalysis (Table 1)⁽⁶⁾.

The shunt consists of a 'pigtail' catheter (Rocket or Harrison) inserted percutaneously under ultrasound guidance through an introducer or trocar. In case the fetus is in anhydramnios, amnioinfusion is required prior to shunt placement. This procedure usually takes only a few minutes and is an outpatient surgery. Complications of the procedure include translocation or mobilization of the catheter or occlusion, necessitating a repeat procedure.

A multicenter clinical trial was conducted in the United Kingdom called PLUTO (Percutaneous vesicoamniotic shunting for fetal Lower Urinary Tract Obstruction). This study compared vesicoamniotic shunt placement and expectant management. A sample size of 150 cases was required for the trial, but only 31 cases were enrolled, so the trial was not completed and anecdotally it was found that there may have been a higher 1-year survival with vesicoamniotic shunting. Fetal intervention for obstructive uropathy therefore currently lacks strong level 1 evidence⁽⁷⁾.

FETAL PLEURAL EFFUSION

Pleural effusion is an accumulation of fluid in the pleural spaces of the fetal chest. The prevalence is 1 in 10,000 pregnancies. Severe effusions, whatever the cause, produce mediastinal compression, leading to pulmonary hypoplasia, hydrops and fetal death⁽⁸⁻¹⁰⁾.

Pleural effusion can be primary or secondary. Primary effusion refers to chylothorax, which is

TABLE 1. REQUIRED PARAMETERS IN UROANALYSIS FOR INTRAUTERINE VESICOAMNIOTIC SHUNT. MODIFIED FROM WILSON RD & JOHNSON MP (2003).

Indicator	Parameter
Sodium	= o < 100mEq/L
Chlorine	= o < 90mEq/L
Calcium	= o < 8mg/dL
Osmolarity	= o < 200mosm/dL
Total protein	= o < 20mg/L
B2 microglobulin	< 6mg/L



the accumulation of lymphatic fluid in the pleural space. Secondary pleural effusion is a collection of serous fluid in the pleural cavity and may be related to congenital malformations, such as heart disease, adenomatous cystic pulmonary malformation, diaphragmatic hernia, bronchopulmonary sequestration, infections or aneuploidy.

Fetuses presenting pleural effusion should be submitted to a study protocol. If pleural effusion is persistent, thoracentesis is recommended to determine if it is a chylothorax, and perform fetal karyotyping, microarrays, as well as viral studies. Fetuses that are candidates for thoracoamniotic shunt placement are those without significant additional fetal anomalies, rapid accumulation after initial thoracentesis and fetal hydrops or symptomatic/progressive polyhydramnios⁽¹¹⁻¹³⁾.

The natural history of untreated isolated fetal pleural effusion has been evaluated by several groups. Aubard et al. performed a review of 204 published cases, finding spontaneous remission of pleural effusion in 22% of cases.

In another review, Ruano found that 50% of fetuses with isolated effusion and untreated hydrops survived. Likewise, 63% of untreated fetuses with isolated effusion without hydrops survived. Rustico et al. in a review of 54 cases of untreated fetal pleural effusion found that 73% of fetuses with isolated pleural effusion without hydrops survived without treatment, as did 35% of fetuses with hydrops. It is important to note that these series do not include data regarding gestational age at delivery, an important variable that could influence the reported results⁽¹⁴⁾.

Pleural effusion with mediastinal deviation or sonographic data of tension is a candidate for treatment. The management of these fetuses is directly related to gestational age. Before 34 weeks gestation, fetal therapy should be offered, as the postnatal risk of a premature fetus with hydrops is high, while the risk of shunt placement is relatively low for the fetus. In cases in which the fetus is 34 weeks or more, it is recommended to induce fetal lung maturity and to perform a fetal thoracentesis under ultrasound guidance before delivery or at the time of cesarean section, thus facilitating neonatal resuscitation⁽¹⁵⁾.

FETAL COMPRESSIVE ASCITES

Fetal ascites is the accumulation of intraperitoneal fluid that can be associated with different causes such as fetal anemia, congenital infections, heart disease, gastrointestinal malformations, genitourinary malformations and fetal hydrops⁽¹⁶⁻¹⁸⁾.

Isolated fetal ascites is a rare entity, and its diagnosis should be differentiated from fetal hydrops which can be caused by major congenital heart disease, aneuploidy, anomalies of the lymphatic system and metabolic alterations, among others. Fetal hydrops is characterized -unlike isolated ascites- by accumulation of fluid in two or more fetal compartments.

The prognosis of fetuses with isolated fetal ascites is directly related to the primary cause, the gestational age at diagnosis, the presence of hydrops, pulmonary hypoplasia in severe ascites and the progression of ascites since these ultrasound findings increase the probability of fetal death⁽¹⁹⁾.

The study protocol in fetuses with fetal ascites consists of requesting irregular antibodies, performing morphologic ultrasound and fetal echocardiography, fetal Doppler with attention to the peak systolic velocity of the middle cerebral artery to rule out fetal anemia, invasive procedure to rule out chromosomopathies, microarrays, study of metabolopathies and viral panel to rule out congenital infections⁽²⁰⁾.

Regarding the treatment of isolated fetal ascites, two options have been reported: paracentesis and peritoneo-amniotic shunt placement.

All fetuses with compressive isolated fetal ascites should undergo paracentesis, which can be diagnostic and therapeutic, allowing improvement of pulmonary function. It prevents pulmonary hypoplasia due to compression of the diaphragm. In case of ascitic fluid reaccumulation, which can occur rapidly, the abdominal-peritoneal shunt is offered, which avoids recurrent paracentesis and therefore reduces the risk of premature delivery and other complications associated with recurrent invasive procedures⁽²¹⁾.



DISCUSSION

Although fetal surgery is a field in development and still under investigation, there are fetal indications that justify an invasive therapeutic procedure since, if not performed, the natural history of the pathology would lead to fetal loss or severe postnatal sequelae. Intrathoracic pathologies with mediastinal compression, aortic stenosis, congenital diaphragmatic hernia, myelomeningocele, lower urinary obstruction, and intrauterine intravascular transfusion, fetofetal transfusion syndrome and TRAP sequence, among others, are the fetal pathologies susceptible to in utero therapy⁽²²⁾.

The International Society for Fetal Medicine and Surgery, in 1982, proposed criteria or basic requirements to submit a fetus to fetal surgery. These criteria are as follows: accurate diagnosis with exclusion of associated anomalies, the natural history of the disease is well documented, and the prognosis established, absence of current effective postnatal therapy, the in-utero procedure has been shown in animal models with demonstration of reversal of the deleterious effects of the condition, the procedure must be performed in multidisciplinary fetal therapy centers with strict protocols and informed parental consent. It is essential to have a multidisciplinary team of experts in prenatal diagnosis, surgical therapy, postnatal care, pediatric surgeon and a team with experience in the operating room, including an anesthesiologist and a neonatologist. Without forgetting the importance that the family should have access to psychosocial support and a specialist in bioethics⁽²³⁾.

In our experience, regarding the management of fetal pathology requiring the placement of a shunt, we have faced different challenges, among them the difficulty in acquiring the appropriate catheter for fetal surgery, such as the Harrison catheter. Under parental consent, the double J catheter for neonatal use has been used in 2 cases.

CASES EXPERIENCE

Case 1

In the first case we received a fetus at the fetal diagnosis and therapy center in which the abdomen was found with distention and intestinal

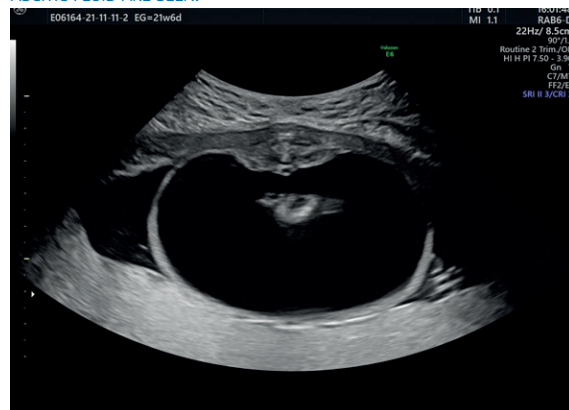
loops suspended in the abdominal cavity, as well as diaphragmatic displacement and thoracic compression (Figure 1). The urinary bladder was observed with normal characteristics surrounded by paravesical arteries; the kidneys appeared normal in size and echotexture (Figure 2). Amniotic fluid was normal for gestational age. The diagnosis of compressive fetal ascites was established. Once the study protocol was performed, fetal anemia was ruled out by obstetric Doppler, maximum systolic peak in normal values for gestational age.

After counseling, fetal amniocentesis and paracentesis were performed to study the viral panel and microarrays, which were found to be negative for viral infection and karyotype 46,XY. Follow-up was done every two weeks, observing recurrence of compressive ascites with diaphragmatic displacement and compression

FIGURE 1. TRANSABDOMINAL ULTRASOUND IMAGE SHOWING MID-SAGITTAL SECTION OF THE ABDOMEN, THORAX AND FETAL HEAD, WITH COMPRESSIVE ASCITES AND DIAPHRAGMATIC DISPLACEMENT.

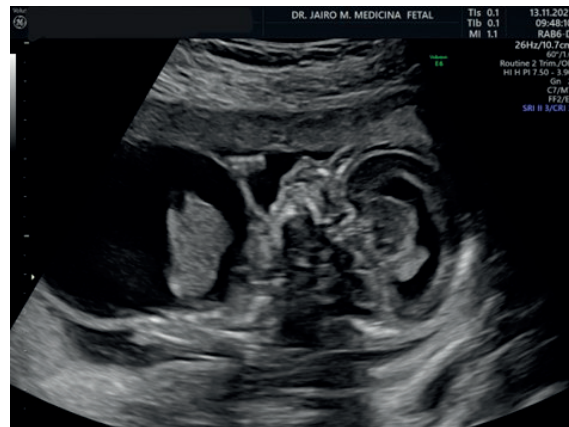

FIGURE 2. TRANSABDOMINAL ULTRASOUND IMAGE SHOWS AXIAL SECTION AT THE LEVEL OF THE FETAL ABDOMEN. BOTH KIDNEYS HAVE NORMAL ULTRASOUND FEATURES AND NO EVIDENCE OF HYDRONEPHROSIS. SEVERE FETAL ASCITES WITH INTESTINAL LOOPS SUSPENDED IN ASCITIC FLUID ARE SEEN.





of pulmonary parenchyma. Under informed consent of the mother, percutaneous fetal surgery was performed for placement of double J catheter (peritoneo-amniotic shunt) (Figure 3). The surgical procedure ended without incident (Figure 4).

Post-surgical fetal follow-up at one week showed thoracic distention, fetal abdomen with mild ascites and functional catheter well placed in the fetal abdominal cavity and amniotic cavity (figure 5). Follow-up was every 4 weeks, finding a fetal growth curve within the normal range. At 37 weeks, a single live product was obtained by cesarean section due to pelvic presentation, male sex, Apgar 6 and 9 at one minute and 5 minutes, respectively, weight 2,800 grams. The newborn had a raisin abdomen and no evidence of fetal pulmonary hypoplasia.

Case 2

A 28-year-old female patient was referred to our fetal diagnosis and therapy center with a diag-

FIGURE 3. SHUNT PLACEMENT KIT. INTRODUCER, GUIDE AND DOUBLE J CATHETER.

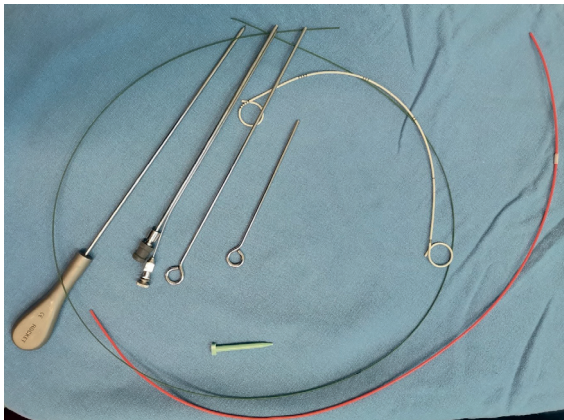


FIGURE 4. PLACEMENT OF PERITONEO-AMNIOTIC SHUNT. THE IMAGE SHOWS AN AXIAL SECTION OF THE FETAL ABDOMEN. INTRODUCTION OF THE ULTRASOUND-GUIDED INTRODUCER INTO THE FETAL PERITONEAL CAVITY IS SEEN.

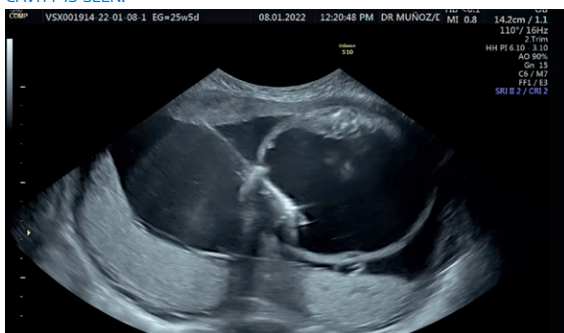
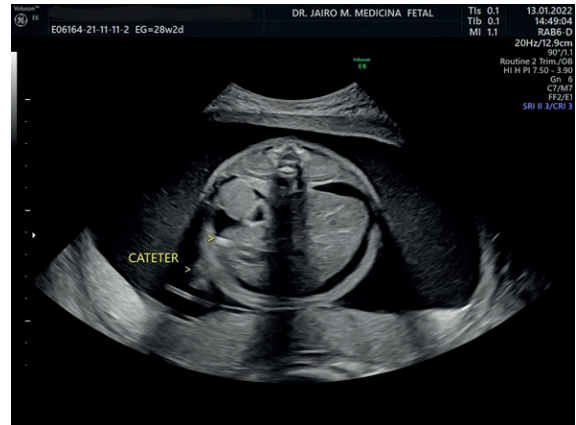
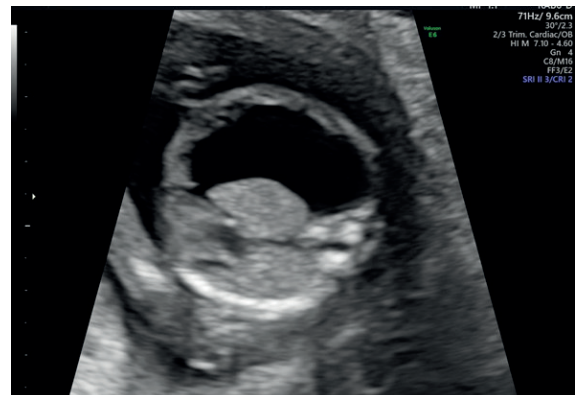FIGURE 5. AXIAL VIEW OF THE ABDOMEN AT THE LEVEL OF THE GASTRIC CHAMBER. THE EVOLUTION IS OBSERVED ONE WEEK AFTER THORACOAMNIOTIC SHUNT PLACEMENT: WELL-PLACED CATHETER AND EXPANSION OF INTRAPERITONEAL ORGANS WITH MILD NON-COMPRESSIVE ASCITES.



nosis of singleton live pregnancy at 17 weeks of gestation and unilateral pleural effusion. Morphological ultrasound was performed, finding a fetus of 18 weeks of gestation without morphological alterations. Fetal echocardiography had no striking findings and fetal neurosonography showed no morphological alterations or echographic markers of second trimester chromosomopathies. Unilateral pleural effusion without mediastinal displacement was evidenced (Figure 6). Counseling was provided and ultrasound follow-up every 2 weeks was decided.

At 26 weeks of gestation persistent unilateral pleural effusion with mediastinal displacement was observed, so it was decided to perform thoracentesis and placement of thoracoamniotic shunt with double J catheter for neonatal use. Ultrasound follow-up at 24 hours showed significant improvement and a well-placed thoracoamniotic shunt (Figure 7).

FIGURE 6. ULTRASOUND IMAGE SHOWING AXIAL SECTION OF THE FETAL THORAX. UNILATERAL PLEURAL EFFUSION WITH DISPLACEMENT OF THE MEDIASTINUM IS OBSERVED.





At 38 weeks of gestation an elective cesarean section was performed, obtaining a single live product with Apgar 8-9, with no evidence of pulmonary hypoplasia; the catheter was found in the amniotic cavity (figure 8).

CONCLUSIONS

With the development of new technology in high-definition ultrasound, different fetal pathologies can be detected in a more timely and accurate manner and, hand in hand with this technological advance, different fetal therapy techniques are being developed.

Percutaneous therapies and especially fetal surgery represent a challenge and a light for a fetal disease that has a mortality rate close to 100% and that can be reversed with the use of these techniques.

In the not distant future, fetal gene therapy or cell therapy will allow the treatment of conditions that today are far from the reach of knowledge.

FIGURE 7. TRANSABDOMINAL ULTRASOUND SHOWING AXIAL SECTION OF THE FETAL THORAX AT THE LEVEL OF THE FOUR CARDIAC CHAMBERS. THORACOAMNIOTIC CATHETER AND HOMOGENEOUS PULMONARY PARENCHYMA ARE OCCUPYING THE THORACIC CAVITY.

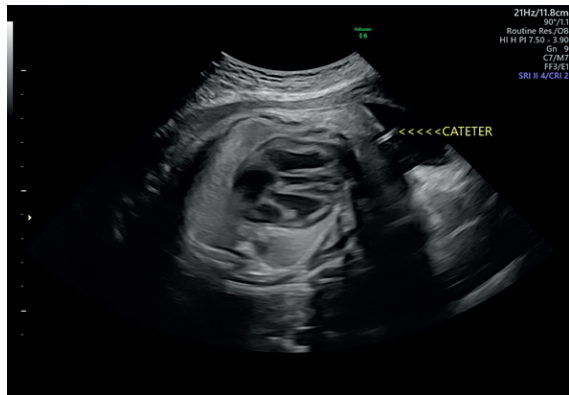
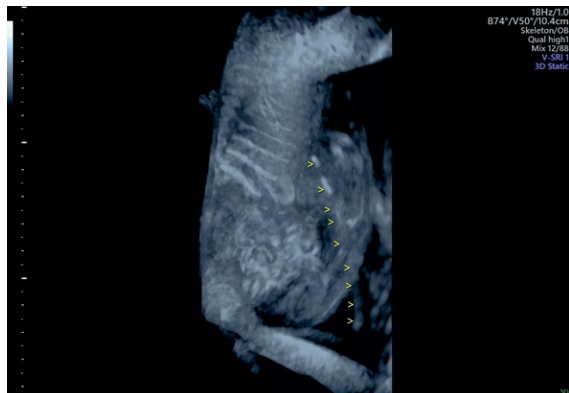


FIGURE 8. 3D RECONSTRUCTION. SAGITTAL IMAGE OF THE FETAL THORAX SHOWING CATHETER ENTERING THE INTERCOSTAL SPACE.



REFERENCES

1. Huamán Guerrero M. Historia de la cirugía fetal. *Rev peru ginecol obstet.* 2019;65(4):479-85. <http://dx.doi.org/10.31403/rpgo.v65i2208>
2. Deprest JA, Flake AW, Gratacos E, Ville Y, Hecher K, Nicolaides K, Johnson MP, Luks FI, Adzick NS, Harrison MR. The making of fetal surgery. *Prenat Diagn.* 2010 Jul;30(7):653-67. doi: 10.1002/pd.2571
3. Brownlee E, Wragg R, Robb A, Chandran H, Knight M, McCarthy L; BAPS-CASS. Current epidemiology and antenatal presentation of posterior urethral valves: Outcome of BAPS CASS National Audit. *J Pediatr Surg.* 2019 Feb;54(2):318-21. doi: 10.1016/j.jpedsurg.2018.10.091
4. Krishnan A, de Souza A, Konijeti R, Baskin LS. The anatomy and embryology of posterior urethral valves. *J Urol.* 2006 Apr;175(4):1214-20. doi: 10.1016/S0022-5347(05)06642-7
5. McHugo J, Whittle M. Enlarged fetal bladders: aetiology, management and outcome. *Prenat Diagn.* 2001 Nov;21(11):958-63. doi: 10.1002/pd.227
6. Ruano R, Ramalho AS, Cardoso AK, Moise K Jr, Zugaib M. Prenatal diagnosis and natural history of fetuses presenting with pleural effusion. *Prenat Diagn.* 2011 May;31(5):496-9. doi: 10.1002/pd.2726
7. Booth P, Nicolaides KH, Greenough A, Gamsu HR. Pleuro-amniotic shunting for fetal chylothorax. *Early Hum Dev.* 1987 Nov;15(6):365-7. doi: 10.1016/0378-3782(87)90031-4
8. Johnson MP, Flake AW, Quintero RA, et al: Fetal shunt procedures. *Invasive Outpatient Procedure in Reproductive Medicine.* Philadelphia, PA, Lippincott-Raven Publishers, pp 6189, 1997.
9. Aubard Y, Derouineau I, Aubard V, Chalifour V, Preux PM. Primary fetal hydrothorax: A literature review and proposed antenatal clinical strategy. *Fetal Diagn Ther.* 1998 Nov-Dec;13(6):325-33. doi: 10.1159/000020863
10. Wilson RD, Johnson MP. Prenatal ultrasound guided percutaneous shunts for obstructive uropathy and thoracic disease. *Semin Pediatr Surg.* 2003 Aug;12(3):182-9. doi: 10.1016/s1055-8586(03)00027-1
11. Rustico MA, Lanna M, Coviello D, Smoleniec J, Nicolini U. Fetal pleural effusion. *Prenat Diagn.* 2007 Sep;27(9):793-9. doi: 10.1002/pd.1768
12. Weber AM, Philipson EH. Fetal pleural effusion: a review and meta-analysis for prognostic indicators. *Obstet Gynecol.* 1992 Feb;79(2):281-6. PMID: 1530987
13. Zeloc C, Benacerraf BR. The causes and natural history of fetal ascites. *Prenat Diagn.* 1994 Oct;14(10):941-6. doi: 10.1002/pd.1970141008
14. Réguerre Y, de Dreuzy O, Boithias C, Lacaze-Masmonteil T, André P, Dehan M. Une cause méconnue d'ascite foetale: l'invagination intestinale aiguë [An unknown etiology of fetal ascites: acute intestinal intussusception]. *Arch Pediatr.* 1997 Dec;4(12):1197-9. French. doi: 10.1016/s0929-693x(97)82608-5
15. Veluchamy M, Ramasamy K, Liyakat N. Isolated Fetal Ascites: A Rare Cause. *Cureus.* 2020 Jun 3;12(6):e8433. doi: 10.7759/cureus.8433



16. de Crespigny LC, Robinson HP, McBain JC. Fetal abdominal paracentesis in the management of gross fetal ascites. *Aust N Z J Obstet Gynaecol.* 1980 Nov;20(4):228-30. doi: 10.1111/j.1479-828x.1980.tb00772.x
17. Baccega F, de Lourdes Brizot M, Jornada Krebs VL, Vieira Francisco RP, Zugaib M. Nonimmune fetal ascites: identification of ultrasound findings predictive of perinatal death. *J Perinat Med.* 2016 Mar;44(2):195-200. doi: 10.1515/jpm-2014-0326
18. Lee YJ, Son SK, Park JH, Song JS, Cheon CK. NEU1 mutation in a Korean infant with type 2 sialidosis presenting as isolated fetal ascites. *Pediatr Neonatol.* 2015 Feb;56(1):68-9. doi: 10.1016/j.pedneo.2014.05.004
19. Harrison MR, Golbus MS, Filly RA, Callen PW, Katz M, de Lorimier AA, Rosen M, Jonsen AR. Fetal surgery for congenital hydronephrosis. *N Engl J Med.* 1982 Mar 11;306(10):591-3. doi: 10.1056/NEJM198203113061006
20. Adzick NS. Prospects for fetal surgery. *Early Hum Dev.* 2013 Nov;89(11):881-6. doi: 10.1016/j.earlhumdev.2013.09.010
21. Bliton MJ. Ethics: "life before birth" and moral complexity in maternal-fetal surgery for spina bifida. *Clin Perinatol.* 2003 Sep;30(3):449-64, v-vi. doi: 10.1016/s0095-5108(03)00046-0