

SYMPOSIUM FETAL SURGERY IN LATIN AMERICAN COUNTRIES

1. Professor of the Faculty of Medical Sciences, Universidad Central del Ecuador. Leader of the Maternal Fetal Unit and head of the National Center for Fetal Medicine and Surgery of the Ministry of Public Health of Ecuador. Director of Fetal Medicine Quito (MFQ), Ecuador. ORCID 0000-0001-7984-1950

Conflict of interest: No conflict with this article.

Funding: Author's own

Received: 13 December 2023

Accepted: 11 January 2024

Online publication: 5 April 2024

Corresponding author:

Dra. Belén Nieto C

✉ bnieto@medicinafetalquito.org

Cite as: Nieto Castro B. Development of fetal surgery in Ecuador, collaboration between assistance and academia, a good practice. *Rev peru gynecol obstet.* 2024;70(1). DOI: <https://doi.org/10.31403/rpgo.v70i2599>

Development of fetal surgery in Ecuador, collaboration between health care and academia, a good practice Desarrollo de la cirugía fetal en Ecuador, colaboración entre la asistencia y la academia, una buena práctica

Belén Nieto Castro¹

DOI: <https://doi.org/10.31403/rpgo.v70i2599>

ABSTRACT

In Ecuador, approximately 250,000 children are born every year. In 2022, there were 1,609 deaths of children under one year of age. Of these deaths, 21.5% were due to congenital anomalies, occupying second place among the ten leading causes of mortality. This reality of fetal, neonatal and infant health has been echoed by international organizations that urge countries to strengthen the timely diagnosis of congenital defects, relying on technological advancement, training of human resources and investment in areas of care of the fetus as a patient, taking into account that some of these defects can be treated in prenatal life, reducing sequelae, and improving the quality of life. In response to these needs, in Ecuador agreements were generated between the University-Academy, Ministry of Public Health-Assistance and private groups dedicated to continuing education, to jointly develop a sustainable fetal health program that benefits fetuses that are carriers of pathologies. In this paper we describe one of the arms of this project that is related to the care of fetuses that can benefit from the advancement of fetal surgery in Ecuador.

Key words: Medicine, fetal, Surgery, fetal, Diagnosis, fetal, Fetal research, Congenital anomalies, Ecuador

RESUMEN

En el Ecuador nacen aproximadamente 250 mil niños al año. En el 2022 se presentaron 1,609 defunciones de menores de un año. De estas muertes, el 21,5% se debieron a anomalías congénitas, ocupando el segundo lugar dentro de las 10 primeras causas de mortalidad. Esta realidad de la salud fetal, neonatal e infantil ha tenido eco en los organismos internacionales que instan a los países a fortalecer el diagnóstico oportuno de los defectos congénitos, apoyándose en el avance tecnológico, formación de recursos humanos e inversión en áreas de atención del feto como paciente, teniendo en cuenta que algunos de estos defectos pueden ser tratados en la vida prenatal, disminuyendo las secuelas y mejorando la calidad de vida. En respuesta a estas necesidades, en el Ecuador se generaron acuerdos entre la Universidad-Academia, Ministerio de Salud Pública-Asistencia y grupos privados dedicados a la educación continua, para en conjunto desarrollar un programa de salud fetal sostenible que beneficie a los fetos que son portadores de patologías. En este artículo describimos uno de los brazos de este proyecto que se relaciona directamente con la atención de fetos que pueden beneficiarse del avance de la cirugía fetal en el Ecuador.

Palabras clave: Medicina fetal, Cirugía fetal, Diagnóstico prenatal, Investigación fetal, Anomalías congénitas, Ecuador

INTRODUCTION

An average of 250,000 children are born annually in Ecuador. During the year 2022, there were 1,609 deaths of children under one year of age; of these deaths, 21.5% were due to congenital anomalies, occupying second place among the 10 leading causes of mortality^(1,2).

This reality is identified in several Latin American countries, which is why in 2020 the Pan American Health Organization urged countries to strengthen adequate and timely prenatal diagnosis⁽³⁾.

Prenatal diagnosis is currently considered a new form of care for the benefit of the mother-fetus binomial, resizing the supply of services in favor of the fetus, who is considered a patient. As a consequence of



the advances in prenatal health, different intra-uterine management and treatments have been developed to improve the possibilities of intra-uterine life and postnatal results.

The history of fetal surgery developed by pediatric surgeons began with Michael Harrison at the University of California and has spread worldwide, maintaining the guidelines of the International Society for Fetal Medicine and Surgery for interventions, these being:

- To have an accurate diagnosis with exclusion of associated anomalies.
- To know the natural history of the disease and the established prognosis.
- That there is no effective postnatal therapy.
- Intrauterine surgery proved to be feasible in animal models and reverses the harmful effects of the alteration.
- The procedure will always be performed by a multidisciplinary team with strict protocols, approved by an ethics committee and with parental consent⁽⁴⁾.

The pathologies that have proven to have a benefit with fetal therapy were also established and are shown in Table 1.

METHODOLOGY

An ecological cross-sectional analytical time series study was carried out, in which data recorded from administrative and legal series of the training process and participation agreements to strengthen interinstitutional fetal medicine in Ecuador was obtained. The article describes in a systematic way the steps taken to generate a sustained advance in fetal surgery in Ecuador, developed by our working group in conjunction with the University, and how continuing education processes have allowed the formation of a Fetal Pathology Management Network.

STEP 1: IMPLEMENTATION OF FETAL DIAGNOSTIC UNITS

The first step was to implement prenatal diagnostic units with a global vision, with a clinical management process mentality that implies knowledge in fetal medicine, information and psychological aspects for parents, multidisciplinary relationship with other specialists, pro-

TABLE 1. PATHOLOGIES THAT HAVE PROVEN TO HAVE A BENEFIT WITH FETAL THERAPY.

Pathology	Effect on the fetus	Justification of therapy
Monochorial pathology Twin-twin transfusion syndrome (TTTS) Acardiac fetus and discordant malformation	TTTS or oligohydramnios-polyhydramnios sequence, hemodynamic changes Premature delivery	Stopping transfusion between twins Reversal of HF Prevent neurological damage Delay delivery
	Risk of damage to the healthy fetus	Decrease risk of healthy fetus (feticide)
Congenital diaphragmatic hernia (CDH)	Hypoplasia Pulmonary hypertension	Reversing pulmonary hypoplasia and preventing pulmonary hypertension
Lower urinary tract obstruction (LUTO)	Renal damage Pulmonary hypoplasia due to oligohydramnios	Prevent kidney damage Restore the amount of AF
Thoracic lesions	Pulmonary hypoplasia (space-occupying mass) Hydrops due to venous return disturbance	Preventing pulmonary hypoplasia and heart failure
Sacroccygeal teratoma	Cardiac insufficiency Fetal anemia	Prevent anemia Prevent heart failure Prevent polyhydramnios
Neural tube defect	Neural tube injury CSF leakage, causing Chiari malformation and ventriculomegaly	Cover exposed spinal cord Stop CSF leakage Prevent ventriculomegaly and reverse cerebellar herniation
Cardiac malformations	Critical lesion with hypoplasia and irreversible damage	Prevent hypoplasia
Chorioangioma	High output heart failure Polyhydramnios	Prevent HF Prevent hydrops
Amniotic flanges or bands	Progressive constrictions Irreversible neurological lesions Vascular damage	Prevent limb deformities and loss of function

CSF: cerebrospinal fluid, HF: heart failure, AF: amniotic fluid. Modified by author from Deprest et al (5)



tolozed management of fetal pathology in the prenatal area, follow-up and postnatal management, seeking consensual and shared obstetric decisions between the health team and the parents. From this level, each specific case has access to subspecialty levels of different complexity, both for making management decisions and for informing parents, but without losing the global concept and the particular character of the fetal patient in its indissoluble binomial with the mother. Thus, it was proposed that fetal pathology cases should be handled from a clinical management process concept.

In this process, the Fetal Diagnosis Unit located in the Isidro Ayora Gynecological and Obstetric Hospital in the city of Quito was established based on an agreement between the Central University of Ecuador and the Ministry of Health to provide care and to train specialists in the field of obstetric ultrasound and fetal medicine.

The process is expanding in the care units of the public and complementary health network in Ecuador, always hand in hand with training by the Faculty of Medicine of the Central University.

STEP 2: CONTINUING EDUCATION IN FETAL MEDICINE AND THE INITIATION OF SURGICAL FETAL THERAPY

Once the Fetal Diagnosis Unit was established with the support of the academy, assistance and teaching activities began. Almost immediately, the need to move from diagnosis to fetal management and therapy was observed, and it was considered vital to have personnel trained in fetal therapy. In addition, it was necessary to strengthen the knowledge of the professionals who were part of the unit in fetal health issues, so several members of the team began training processes within and outside the country.

Once the health professionals were trained and maintaining the coordinated work with the academy in response to the co-participation agreement, the first surgery was performed in July 2020 by our group. It was a placental laser for twin-twin transfusion syndrome and so far at least 41 intrauterine procedures have been performed, among which laser surgery in monochorionic pathology ranks first (Figure 1), followed by the repair of neural tube defects myelome-

ningocele, which has been performed with the open technique (Figure 2). Thoracoamniotic shunts have been placed in hydrothorax, endotracheal balloon has been inserted in cases of congenital diaphragmatic hernia to improve the postnatal prognosis of these newborns (Figure 3), diagnostic cystoscopies were performed, one of which was also therapeutic. Although not considered as surgery, but implying previous preparation and experience, we performed intrauterine blood transfusions and thoracentesis.

STEP 3: CONSTITUTION, FORMATION AND INAUGURATION OF THE NATIONAL CENTER FOR FETAL MEDICINE AND SURGERY

From the first fetal surgery performed by our group in 2020, work began to create a national Center that could respond to the public health needs of our country.

The justification for the creation of a National Center for Fetal Medicine and Surgery was not only based on the right to health and the vision of the fetus as a patient but also, based on a cost-effectiveness analysis, to provide timely prenatal care to reduce the number of sequelae and preterm deliveries resulting from traditional management. In some pathologies, such as twin-twin transfusion syndrome, it is possible to reduce the number of days of neonatal intensive care and the public health and social costs.

This project had an echo in the health authorities, who gave all their support for the achievement of this project. The investment included:

- Differentiated physical spaces or areas that allow offering rapid quality care with warmth, respecting confidentiality and favoring multi-

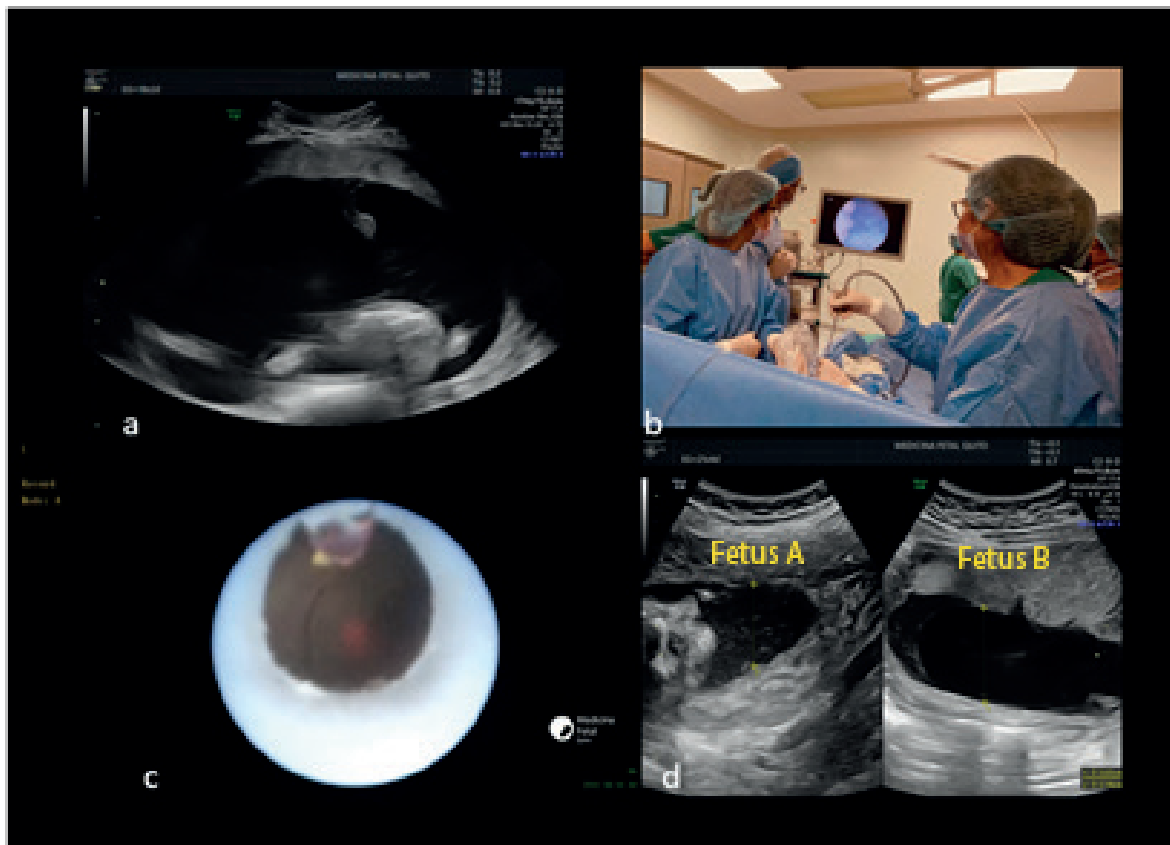
TABLE 2. SUMMARY OF FETAL PROCEDURES PERFORMED BETWEEN JULY 2020 AND NOVEMBER 2023.

Pathology	Procedures	N
Monochorionic pathology	Placental laser	20
Neural tube defect (NTD)	NTD repair, open technique	9
Congenital diaphragmatic hernia	Endotracheal balloon placement	2
Lower urinary obstruction	Cystoscopy	2
Hydrothorax	Thoracoamniotic catheter	1
Hydrothorax	Thoracentesis	3
Bronchopulmonary sequestration	Laser ablation of nutrient vessel	1
Fetal anemia	Intrauterine fetal blood transfusion	4

HGOIA-HGONA- MFQ data, reported by the author



FIGURE 1. PLACENTAL LASER FOR TTTS (TWIN-TWIN TRANSFUSION SYNDROME): A. RECIPIENT FETUS WITH POLYHYDRAMNIOS; B. FETAL SURGERY TEAM; C. IDENTIFICATION OF INTERFETAL VASCULAR COMMUNICATIONS; D. POST-SURGICAL CONTROL WITH NORMALIZATION OF AMNIOTIC FLUID IN BOTH FETUSES. THIS SURGERY HAS SHOWN BENEFIT IN THE MANAGEMENT OF MONOCHORIONIC PATHOLOGY. THE CASE PRESENTED WAS IN QUINTERO STAGE II⁽⁶⁾.



disciplinary care, counseling and support to parents.

- Equipment: fetal health requires the use of the latest technology for both diagnosis and surgery, the use of appropriate devices to reduce the risks of the procedures.
- Human resources with knowledge in fetal health and diagnostic procedures and fetal therapy, as well as the sensitivity to accompany parents during their pregnancy.

The Nueva Aurora Pediatric Obstetric and Gynecological Hospital 'Luz Elena Arismendi' was designated as the hospital where this center would be developed. And with an investment of approximately USD 568,329.16, the National Center for Fetal Medicine and Surgery was inaugurated on October 31, 2023.

CONCLUSIONS

- The implementation of fetal surgery services should be the result of a systematic process that firstly allows the training of human talent from universities and in partnership with hospitals of the health network.
- The sustainability of the process is achieved by the participative association between academia, health care and private areas.
- In Latin American countries, in order to optimize both training and assistance resources, reducing the costs generated by fetal surgery by working jointly with professionals from the public and private areas, in a national center where the necessary infrastructure to carry out these surgeries is implemented, seems to be a cost-effective practice.



FIGURE 2. MYELOMENINGOCELE REPAIR WITH OPEN FETAL SURGERY TECHNIQUE: A. FETAL SPINE WITH LUMBOSACRAL NEURAL TUBE DEFECT; B. FETAL HEAD WITH BILATERAL VENTRICULOMEGALY; C. VISUALIZATION OF THE DEFECT THROUGH THE HYSTEROTOMY; D. END OF NEUROSURGERY, DEFECT REPAIRED BY PLANES; E. THE SCAR IS OBSERVED ON THE SKIN OF THE NEWBORN; F. FETAL SURGERY TEAM. INTRAUTERINE REPAIR WAS SHOWN TO REDUCE THE NEED FOR VENTRICULO-PERITONEAL SHUNT VALVE PLACEMENT AND INCREASE THE CHANCES OF INDEPENDENT AMBULATION⁽⁷⁻⁸⁾. THE IMAGES CORRESPOND TO A CASE REFERRED TO OUR CENTER FROM EASTERN ECUADOR.

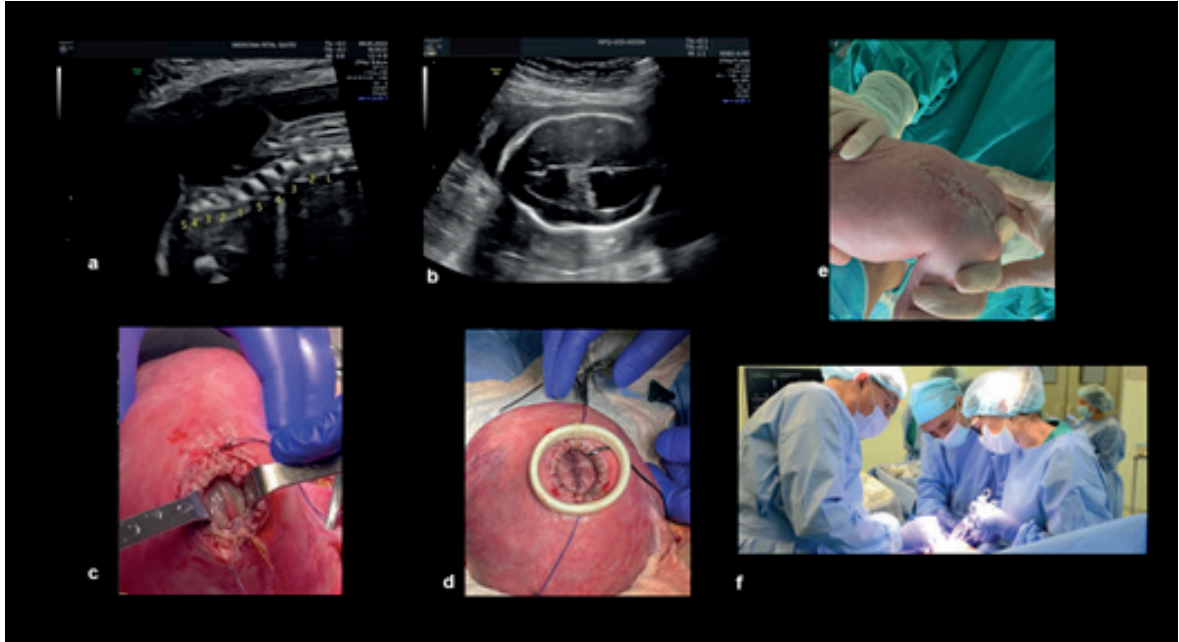
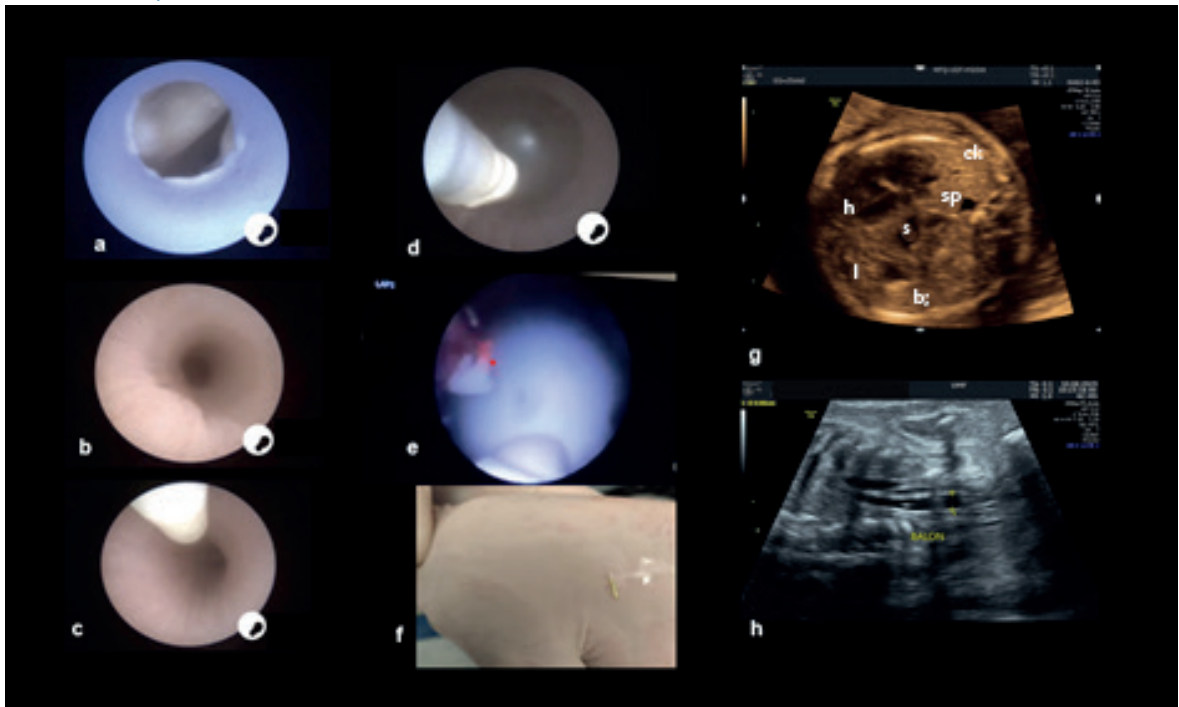


FIGURE 3. SEQUENCE OF ENDOTRACHEAL BALLOON (FETO) PLACEMENT FOR CONGENITAL DIAPHRAGMATIC HERNIA: A. VOCAL CORDS; B. TRACHEA; C. INSERTION OF THE BALLOON INTO THE TRACHEA; D. BALLOON INFLATED BETWEEN THE CARINA AND THE VOCAL CORDS; E. BALLOON PRIOR TO REMOVAL, LASER FIBER TO DEFLATE; F. BALLOON REMOVED; G. IMAGE OF THE CHEST WITH CDH (H: HEART, CL: CONTRALATERAL LUNG, S: STOMACH, SP: SPLEEN, I: LIVER; B: INTESTINE); H ENDOTRACHEAL BALLOON CONTROL. STUDIES HAVE SHOWN THAT FETO IS ASSOCIATED WITH INCREASED SURVIVAL OF FETUSES WITH SEVERE CDH, FROM 40% TO 15% WITHOUT THERAPY. THIS CASE HAD SEVERE PULMONARY HYPOPLASIA⁽⁹⁻¹⁰⁾.





ACKNOWLEDGEMENTS

To the authorities and health professionals of the Nueva Aurora Luz Elena Arismendi and Isidro Ayora Gynecological and Obstetric Pediatric Obstetric Hospitals, as well as to the authorities of the Universidad Central del Ecuador, to the entire teaching staff of Medicina Fetal Quito and especially to our Academic Coordinator Dr. Eduardo Yépez G, for his collaboration in the development of this article.

REFERENCES

1. Estadísticas Vitales, Registro Nacional de Nacidos Vivos y Defunciones Fetales 2022, Instituto Nacional de Estadísticas y Censo, junio 2023. https://www.ecuadorencifras.gob.ec/documentos/web-inec/Poblacion_y_Demografia/Nacimientos_Defunciones/Nacidos_vivos_y_def_fetales_2022/Presentacion_ENV_y_EDF_2022.pdf
2. Estadísticas vitales, Registro de Estadísticas de Defunciones Generales de 2022, Instituto Nacional de Estadísticas y Censo, septiembre 2023. <https://www.ecuadorencifras.gob.ec/defunciones-generales/>
3. Presente y Futuro de la Vigilancia de Defectos Congénitos en las Américas, Organización Panamericana de la Salud y Banco Internacional de Reconstrucción y Fomento, Banco Mundial, Washington, D.C.: OPS, Banco Mundial; 2020. ISBN: 978-92-75-32192-8
4. Deprest J, Devlieger R, Srisupundit K, Beck V, Sandaite I, Rusconi S, et al. Fetal Surgery is a clinical reality. *Semin Fetal Neonatal Med.* 2010 Feb;15(1):58-67. doi: 10.1016/j.siny.2009.10.002
5. Deprest JA, Done E, Van Mieghem T, Gucciardo L. Fetal surgery for anesthesiologists. *Curr Opin Anaesthesiol.* 2008 Jun;21(3):298-307. doi: 10.1097/ACO.0b013e3282ff8607
6. Kontopoulos E, Chmait RH, Quintero RA. Twin-to-Twin Transfusion Syndrome: Definition, Staging, and Ultrasound Assessment. *Twin Res Hum Genet.* 2016 Jun;19(3):175-83. doi: 10.1017/thg.2016.34
7. Meller C, Covini D, Aiello H, Izbizky G, Portillo Medina S, Otaño L. Update on prenatal diagnosis and fetal surgery for myelomeningocele. *Arch Argent Pediatr.* 2021 Jun;119(3):e215-e228. English, Spanish. doi: 10.5546/aap.2021.eng.e215
8. Sanz Cortes M, Chmait RH, Lapa DA, Belfort MA, Carreras E, Miller JL, et al. Experience of 300 cases of prenatal fetoscopic open spina bifida repair: report of the International Fetoscopic Neural Tube Defect Repair Consortium. *Am J Obstet Gynecol.* 2021 Dec;225(6):678.e1-678.e11. doi: 10.1016/j.ajog.2021.05.044
9. Cruz-Martínez R, Etchegaray A, Molina-Giraldo S, Nieto-Castro B, Gil Guevara E, Bustillos J, et al; Latin American CDH Study Group. A multicenter study to predict neonatal survival according to lung-to-head ratio and liver herniation in fetuses with left congenital diaphragmatic hernia (CDH): hidden mortality from the Latin American CDH Study Group Registry. *Prenat Diagn.* 2019 Jun;39(7):519-26. doi: 10.1002/pd.5458
10. Deprest JA, Nicolaides KH, Benachi A, Gratacos E, Ryan G, Persico N, et al; TOTAL Trial for Severe Hypoplasia Investigators. Randomized Trial of Fetal Surgery for Severe Left Diaphragmatic Hernia. *N Engl J Med.* 2021 Jul 8;385(2):107-18. doi: 10.1056/NEJMoa2027030