

CASE REPORT

1. Clínica Científica, Trujillo, Perú; Hospital Regional Docente de Trujillo, Perú; Medicina Fetal México, Guadalajara, México. ORCID 0000-0002-1273-8032
2. Centro de Reproducción Asistida Fertilita, Trujillo, Perú; Universidad Nacional de Trujillo, Perú; Hospital Regional Docente de Trujillo, Perú. ORCID 0000-0001-6336-1493

Funding: Self-financed.

Conflict of interest: None.

Ethical considerations: The authors report having followed data confidentiality protocols on the publication of patient information. The ethics committee of the Hospital Regional Docente de Trujillo reviewed and accepted the patient's informed consent, which was requested by the authors.

Received: 25 August 2023

Accepted: 4 October 2023

Online publication : 6 December 2023

Corresponding author:

Dr. Orlando Salazar Rengifo

📍 Clínica Científica, calle José Gil de Castro 586, Urbanización El Bosque, Trujillo, Perú

☎ +51 969168100

✉ orlandosalazarperu@gmail.com

Cite as: Salazar Rengifo O, Rojas Ruiz JC. First reported case in Peru of fascia lata sling in stress urinary incontinence. *Rev peru ginecol obstet.* 2023;69(4). DOI: <https://doi.org/10.31403/rpgo.v69i2571>

First reported case of fascia lata sling in stress urinary incontinence in Peru

Primer caso comunicado en el Perú de cabestrillo de fascia lata en incontinencia urinaria de esfuerzo

Orlando Salazar Rengifo¹, Juan Carlos Rojas Ruiz²

DOI: <https://doi.org/10.31403/rpgo.v69i2571>

ABSTRACT

Stress urinary incontinence is common in women from middle adulthood onwards. The most frequent technique to treat these cases is the synthetic sling. However, the autologous sling has good results comparable with the synthetic material in the various studies published. We present a case treated with fascia lata sling, describing the technique and evolution.

Key words: Urinary incontinence, stress, Suburethral slings, Transplantation, autologous, Fascia lata

RESUMEN

La incontinencia urinaria de esfuerzo es frecuente en las mujeres desde la adultez media. La técnica más frecuente para tratar estos casos es el cabestrillo sintético. Sin embargo, el cabestrillo autólogo tiene buenos resultados comparables con el material sintético en los diversos estudios publicados. Presentamos un caso tratado con cabestrillo de fascia lata, describiendo la técnica y evolución.

Palabras clave: Incontinencia urinaria, esfuerzo, Cabestrillo suburetral, Trasplante autólogo, Fascia lata

INTRODUCTION

According to the International Continence Society, the definition of urinary incontinence is involuntary urinary leakage through the urethra, which results in a social-hygienic problem. It is clinically divided into stress urinary incontinence (SUI), urge urinary incontinence or both⁽¹⁾. The prevalence of SUI in middle-aged and postmenopausal women is as high as 57%. A complete assessment including history is necessary to determine the type of urinary incontinence and the therapeutic plan⁽²⁾.

The use of autologous material around the urethra as a treatment for SUI is not a new concept. Techniques have been described with fascia sling of the gracilis, pyramidalis, levator ani, bulbocavernosus, rectus abdominis and external oblique muscles. Beck et al. pioneered the use of the fascia lata sling (FLS) in SUI, resulting in 92% resolved symptomatology in 170 women⁽³⁾. In the controversy of autologous sling and synthetic sling (SS), the most scientifically valid randomized clinical study by Arunkalaivanan and Barrington, who demonstrated equal healing rates of biological material sling compared to SS (89% and 85%, respectively), has been performed⁽⁴⁾. Similarly, Wadie et al. reported 92% success with autologous sling compared to 92.9% with SS⁽³⁾. A success rate with autologous material of 87-92% is reported⁽⁵⁾, compared to 70-80% with synthetic material. Most publications agree that SS has an increased risk of mesh erosion and infection^(6,7).

Currently there are more than 100 surgical techniques for the correction of SUI, with increasing use of autologous slings and decreasing use of SS, according to notifications from the Food and Drug Administration (FDA)⁽⁸⁾. SS is considered the gold standard for surgical treatment of SUI. However, autologous slings are usually placed if synthetic slings fail,

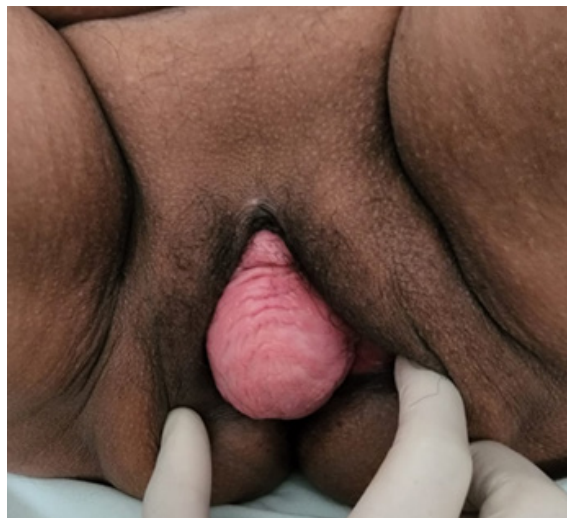because of contraindications to the synthetic material or because the patient prefers to avoid them. There has been an alert issued by the Royal College-Commonwealth of Nations and the subsequent communication by the FDA to stop the sale of SS for pelvic organ prolapse, warning of the risks of its use^(9,10). As the usage of FLS has been shown to have good results, it could be considered a primary technique for SUI^(11,12).

CASE REPORT

A 60-year-old housewife with a history of 3 vaginal deliveries reported cessation of sexual activity and sensation of mass in the vagina for 3 years due to urinary leakage on medium exertion and frequency of urine spurts without urinary urgency. The patient was evaluated in the gynecology department of the Hospital Regional Docente de Trujillo, Peru, with a neurourological clinical history, questionnaire for SUI, physical examination, general urine examination and colposcopy with normal results. She was classified as having severe SUI, with 8 points according to the Incontinence Severity Index (ISI)⁽¹³⁾ and grade IV by the Pelvic Organ Prolapse Quantification System (POPQ). Once the diagnosis of total genital prolapse (Figure 1) and SUI was confirmed, it was proposed to perform colpocleisis, perineoplasty and removal of fascia lata graft for placement of a sling at the suburethral level.

The surgical procedure was performed in the right lateral decubitus position to expose the left thigh. A longitudinal incision was made 10

FIGURE 1. TOTAL GENITAL PROLAPSE WHEN APPLYING THE VALSALVA MANEUVER.



cm above the level of the lateral condyle of the femur until the fascia lata was exposed. This was dissected, obtaining 10 x 4 cm of tissue that was immersed in saline solution for its subsequent preparation (Figure 2).

Hemostasis was checked and Penrose drain was left at the muscle level. Simultaneously to the preparation of the fascia lata tissue, Lefort colpocleisis was performed with extraction of the anterior and posterior rectangle of the vaginal mucosa, leaving both lateral spaces of 2 centimeters covered by mucosa. Then the 2 portions of the rectangles were approximated until total invagination of the prolapse and total closure of the vagina. Subsequently, the suburethral vaginal mucosa was dissected with bilateral incision up to the aponeurosis at the intersection of the inguocrural fold at the level of the clitoris. The transobturator fascia lata autograft was placed in the mid-suburethral area, free of tension (Figure 3). The patient tolerated the surgical procedure well and was discharged in 72 hours.

FIGURE 2. (A) FASCIA LATA MARKED WITH THE WHITE ARROW, (B) PREPARATION OF THE FASCIA LATA TISSUE BY REMOVING RESIDUAL ADHERENT MATERIAL.

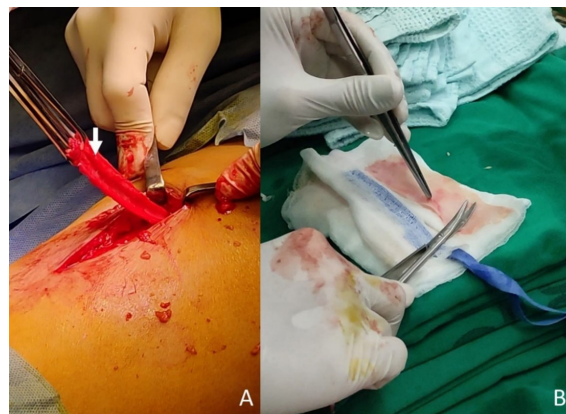
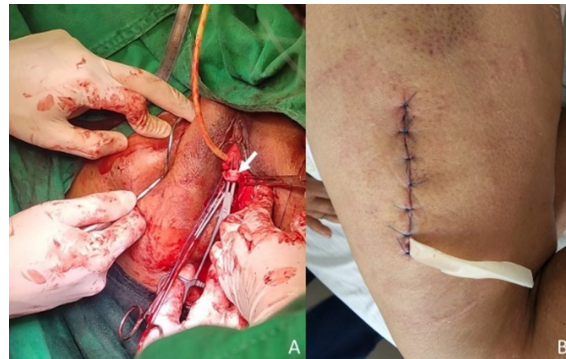


FIGURE 3. (A) PLACEMENT OF THE FASCIA LATA SLING, INDICATED BY THE WHITE ARROW, IN THE SUBURETHRAL REGION. (B) OPERATIVE WOUND SUTURED AT THE THIGH LEVEL WITH PLACEMENT OF THE PENROSE DRAIN.





The patient was evaluated after 7 days, at 6 months and at one year. In the last evaluation the ISI test was performed (0 points), showing total improvement of the symptomatology. There were no complications in the 12 months of follow-up for the pre-existing problems of genital prolapse and SUI (Figure 4).

DISCUSSION

For some years now, observations have arisen regarding SS⁽⁸⁻¹⁰⁾, making us reconsider its success rate to be considered as the gold technique. The main associated complications are mesh erosion and infections^(7,12), which could be due to the fact that the immune system recognizes the synthetic material as a foreign body, as well as to the condition of hypoestrogenism of patients with genital prolapse who usually develop atrophy of the vaginal mucosa. This facilitates the exposure of the mesh as the most frequent late complication and reason for consultation in the follow-up of patients treated surgically with SS.

The tendency has been to find materials that provide comparable or better results, such as xenografts (porcine and bovine), with few reports and recommendations regarding SUI⁽⁵⁾, allografts (human cadaveric material of fascia lata prepared with dehydrated solvent and gamma irradiation) related to autolysis, poor functionality and high potential for disease transmission⁽¹²⁾. Huang et al. demonstrated poor results using cadaveric tissue with failure rate of 27.8% compared to 4% of autologous material for SUI correction⁽¹⁴⁾.

Peng et al. report that the FLS can decrease perioperative morbidity by presenting fewer operative site complications without functional

compromise compared to the rectus abdominis sling⁽¹¹⁾. Also, Shaw et al. concluded that patients treated with FLS had preserved function, high satisfaction and minimal thigh pain at a 9-month follow-up⁽⁹⁾. The fascia lata is an abductor and external rotator of the lower limbs and its use in the technique has not been associated with any functional-motor or nerve deficit. Latini et al. showed in an average follow-up of 4.4 years an 83% satisfaction and intention to recommend in patients treated with FLS⁽¹²⁾.

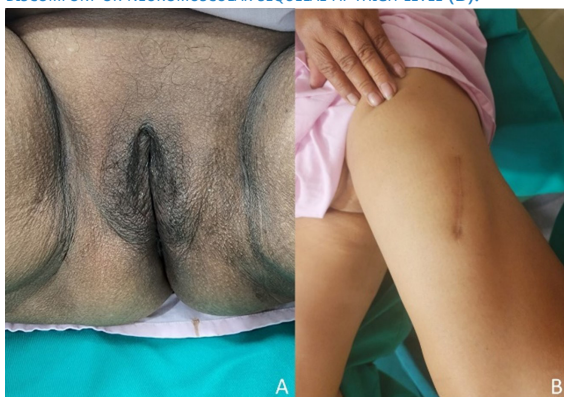Based on the good results with the use of autologous FLS material and considered as a primary technique in third level reference centers worldwide⁽⁸⁾, the first case performed in Peru with the use of this material for SUI correction is published. The technique presented a fairly short learning curve⁽¹²⁾ and had a successful result according to the questionnaire validated in Spanish for the SUI problem⁽¹³⁾.

It has been inferred that the FLS would have the same results as the SS, being able to be considered as a primary technique for SUI⁽¹²⁾. More studies are necessary to determine its secondary effects as well as its long term efficiency.

REFERENCES

1. Capobianco G, Madonia M, Morelli S, Dessole F, De Vita D, Cherchi PL, et al. Management of female stress urinary incontinence: A care pathway and update. *Maturitas*. March 2018;109:32-8. DOI: 10.1016/j.maturitas.2017.12.008
2. Sussman RD, Syan R, Brucker BM. Guideline of guidelines: urinary incontinence in women: Urinary incontinence in women. *BJU Int*. May 2020;125(5):638-55. DOI: 10.1111/bju.14927
3. Bayrak Ö, Osborn D, Reynolds WS, Dmochowski RR. Pubovaginal sling materials and their outcomes. *Turk J Urol*. December 2014;40(4):233-9. DOI: 10.5152/tud.2014.57778
4. Arunkalaivanan AS, Barrington JW. Randomized trial of porcine dermal sling (Pelvic implant) vs. tension-free vaginal tape (TVT) in the surgical treatment of stress incontinence: a questionnaire-based study. *Int Urogynecol J Pelvic Floor Dysfunct*. 2003 Feb;14(1):17-23. DOI: 10.1007/s00192-002-1000-9
5. Kobashi KC, Albo ME, Dmochowski RR, Ginsberg DA, Goldman HB, Gomelsky A, et al. Surgical Treatment of Female Stress Urinary Incontinence: AUA/SUFU Guideline. *J Urol*. October 2017;198(4):875-83. DOI: 10.1016/j.juro.2017.06.061
6. U.S. Food & Drug Administration. Considerations about Surgical Mesh for SUI. FDA [Internet]. 04/16/2019. <https://www.fda.gov/medical-devices/urogynecologic-surgical-mesh-implants/considerations-about-surgical-mesh-sui>
7. Cornu JN, Peyrat L, Haab F. Update in Management of Vaginal Mesh Erosion. *Curr Urol Rep*. October 2013;14(5):471-5. DOI: 10.1007/s11934-013-0357-2

FIGURE 4. CONTROL AT ONE YEAR AFTER SURGERY (A), WITHOUT URINARY DISCOMFORT OR NEUROMUSCULAR SEQUELAE AT THIGH LEVEL (B).





8. Rac G, Younger A, Clemens JQ, Kobashi K, Khan A, Nitti V, et al. Stress urinary incontinence surgery trends in academic female pelvic medicine and reconstructive surgery urology practice in the setting of the food and drug administration public health notifications: SUI Surgery Trends. *Neurourol Urodyn*. April 2017;36(4):1155-60. DOI: 10.1002/nau.23080
9. Shaw JS, Gerjevic KA, Pollack C, Strohbehn K. Minimally Invasive Autologous Fascia Sling at the Midurethra: A Case Series. *J Minim Invasive Gynecol*. October 2022;29(10):1165-9. DOI: 10.1016/j.jmig.2022.07.001
10. Urogynecologic Surgical Mesh Implants | FDA [Internet]. [cited 6 August 2023]. <https://www.fda.gov/medical-devices/implants-and-prosthetics/urogynecologic-surgical-mesh-implants>
11. Peng M, Sussman RD, Escobar C, Palmerola R, Pape DM, Smilen SS, et al. Rectus Fascia Versus Fascia Lata for Autologous Fascial Pubovaginal Sling: A Single-Center Comparison of Perioperative and Functional Outcomes. *Female Pelvic Med Reconstr Surg*. August 2020;26(8):493-7. DOI: 10.1097/SPV.0000000000000761
12. Latini JM, Lux MM, Kreder KJ. Efficacy and Morbidity of Autologous Fascia Lata Sling Cystourethropey. *J Urol*. March 2004;171(3):1180-4. DOI: 10.1097/01.ju.0000111807.67599.8d
13. Sandvik H, Espuna M, Hunskaar S. Validity of the incontinence severity index: comparison with pad-weighting tests. *Int Urogynecology J*. October 2006;17(5):520-4. DOI: 10.1007/s00192-005-0060-z
14. Huang YH, Lin ATL, Chen KK, Pan CC, Chang LS. High failure rate using allograft fascia lata in pubovaginal sling surgery for female stress urinary incontinence. *Urology*. December 2001;58(6):943-6. DOI: 10.1016/S0090-4295(01)01430-3