

CASE REPORT

1. Medical Specialist in Gynecology and Obstetrics, Subspecialist in Human Reproductive Biology, Professor of the Universidad Nacional de Trujillo, Peru. Assistant Physician of the Regional Teaching Hospital of Trujillo, Peru. Medical Director of the Assisted Reproduction Center FERTILITA, Trujillo, Peru. ORCID 0000-0001-6336-1493
2. Medical Specialist in Gynecology and Obstetrics, Assisted Reproduction Center Physician FERTILITA, Trujillo, Peru. ORCID 0000-0002-6833-730X
3. Specialist in Gynecology and Obstetrics, Specialist in Family and Community Medicine, Professor at Universidad César Vallejo, Trujillo, Peru. Attending physician at Hospital de Especialidades Básicas La Noria, Trujillo, Peru ORCID 0000-0003-4658-2897

Ethical criteria

Confidentiality of data: The authors declare that they followed their center's protocols on the publication of patient data.

Right to privacy and informed consent: The authors declare that they requested informed consent from the patient, which was reviewed and accepted by the ethics committee of FERTILITA.

Conflicts of interest: The authors deny conflicts of interest.

Funding: Self-funded.

Authors' contribution: All authors participated in the present study. They were responsible for the evaluation of the clinical case, drafted the first version of the article, participated in the discussion of the studies found, approved the final version of the manuscript, and assume responsibility for the content of the article.

Received: 9 May 2023

Accepted: 13 October 2023

Online publication: 6 December 2023

Correspondencia:

Juan Carlos Rojas Ruiz

📍 Calle los Diamantes 283, Urbanización Santa Inés, Trujillo, Perú. Código postal 13001

☎ 949067591

✉ jcrojasru@gmail.com

Cite as: Rojas-Ruiz JC, Salazar-Cuba X, Ángeles-Reyes RP. Egg donation following ischemic ovarian detorsion for twisted pedicle due to paratubal cyst. *Rev peru ginecol obstet.* 2023;69(4). DOI: <https://doi.org/10.31403/rpgo.v69i2570>

Oocyte donation following ischemic ovarian detorsion for twisted pedicle due to paratubal cyst

Donación de óvulos posterior a detorsión de ovario isquémico por pedículo torcido debido a quiste paratubárico

Juan C. Rojas-Ruiz¹, Xanadu Salazar-Cuba², Robert P. Ángeles-Reyes³

DOI: <https://doi.org/10.31403/rpgo.v69i2570>

ABSTRACT

Adnexal torsion is secondary to generally benign ovarian cysts. The usual surgery is salpingo-oophorectomy. However, to maintain ovarian function, minimally invasive surgery with detorsion and preservation of the ovary is recommended regardless of its appearance. We present the case of a 19-year-old woman diagnosed with twisted pedicle cyst, who underwent laparoscopic detorsion of the twisted pedicle and excision of the paratubal cyst with ovarian preservation, despite its ischemic aspect. The patient presented favorable evolution and participated in an ovidonation program, obtaining oocytes from the previously affected ovary in similar quantity and quality to the unaffected ovary. Laparoscopic ovarian detorsion and preservation of the involved ovary regardless of its appearance is a safe and effective procedure to preserve fertility. **Key words:** Ovarian torsion, Ovarian reserve, Oocyte donation

RESUMEN

La torsión anexial es secundaria a quistes ováricos generalmente benignos. La cirugía habitual es la salpingooferectomía. Sin embargo, para mantener la función ovárica se recomienda una cirugía mínimamente invasiva con detorsión y conservación del ovario independientemente de su apariencia. Presentamos el caso de una mujer de 19 años con diagnóstico de quiste a pedículo torcido, a quien se realizó detorsión laparoscópica del pedículo torcido y exéresis del quiste paratubárico con preservación de ovario, a pesar del aspecto isquémico. La paciente presentó evolución favorable y participó en un programa de ovodonación, obteniéndose ovocitos del ovario antes afectado en cantidad y calidad similar al ovario no afectado. La detorsión ovárica laparoscópica y conservación del ovario comprometido independientemente de su apariencia es un procedimiento seguro y eficaz para preservar la fertilidad. **Palabras clave:** Torsión ovárica, Reserva ovárica, Donación de ovocito

INTRODUCTION

Adnexal torsion is the fifth most common gynecologic emergency; 30% occurs in women under 20 years of age⁽¹⁾. This pathology is associated with functional ovarian cysts, benign teratomas and paratubal cysts⁽²⁾. The most common symptom is abdominal pain of sudden onset, intermittent, non-radiating and accompanied by nausea and vomiting. If ovarian torsion is suspected, laparoscopy is indicated to preserve tubo-ovarian function and future fertility⁽³⁾.

It should be kept in mind that there are insufficient clinical or imaging criteria to confirm the preoperative diagnosis, and Doppler flowmetry guides decision making.

The diagnosis of adnexal torsion is surgical. A minimally invasive approach with detorsion and preservation of the adnexal structures is recommended, regardless of the appearance of the ovary. However, the usual surgery performed is salpingo-oophorectomy. A surgeon should not remove an ovary with torsion unless oophorectomy is unavoidable, such as in the case of a severely necrotic ovary⁽²⁾.



Ovodonation is the process by which a woman donates eggs for the purpose of using them in an assisted reproductive technique or for biomedical research⁽⁴⁾. The American Society for Reproductive Medicine (ASRM) recommends a baseline evaluation of the donor to measure her ovarian reserve by antral follicle count (AFR) and/or measurement of serum biomarkers⁽⁵⁾.

Previous studies suggest that ovarian preservation after adnexal detorsion is safe and that the ovarian reserve reflected by AFR is not compromised⁽¹⁾. Balasubramaniam et al. report that out of 46 detorsion attempts they preserved 45 ovaries (97.8%). Most of the pathologies were benign. All preserved ovaries showed ovarian structure, follicles and vascularization maintained during ultrasound follow-up, concluding that laparoscopic ovarian detorsion, even in severely ischemic ovaries, is the best treatment modality regardless of the degree of ischemia⁽⁶⁾. Likewise, Asfour et al. studied histologically the ovaries removed in patients with twisted pedicle cyst and found preserved oocyte follicles in 62.6% of cases, implying preserved ovarian function in the vast majority of patients who underwent oophorectomy for ovarian torsion⁽⁷⁾.

Despite growing evidence supporting detorsion without oophorectomy, unfounded myths and non-evidence-based statements remain, including the risk of ovarian vein thrombosis, nonviability of ovarian tissue, and ovarian functional loss, contributing to the practice of oophorectomy⁽¹⁾. We report the case of a patient in whom the ovary was preserved and subsequently participated in an oocyte donation program.

CASE REPORT

A 19-year-old woman was brought to the emergency room for one week of moderate abdominal colicky pain that intensified in the last 4 hours associated with nausea. On examination she had stable vital signs, painful abdomen on superficial and deep palpation predominantly in the right iliac fossa. There was pelvic pain on mobilization of the cervix. Ultrasound showed an anechogenic image in the right adnexa measuring 102 x 85 mm with presence of free fluid. Doppler was negative. Ancillary tests were within normal parameters. Pregnancy test was negative.

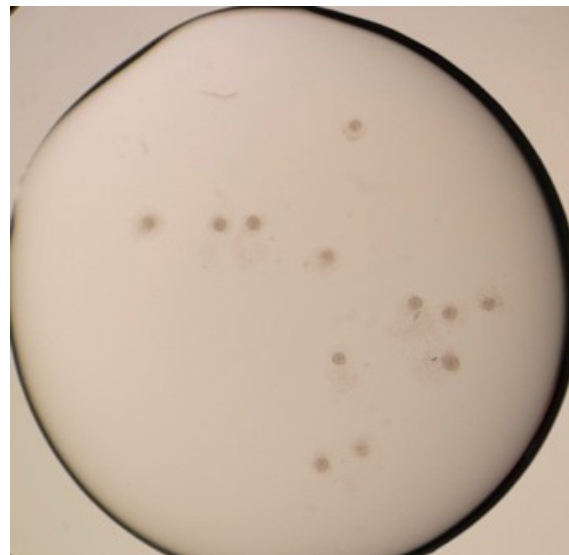
With the diagnosis of acute gynecological abdomen, laparoscopy was performed and a 10 cm violaceous paratubal cyst was found, involving the tube and the right ovary, twisted 3 times on its pedicle. In addition, the ovary had bluish-black coloration and presence of serous fluid of approximately 100 mL (Figure 1). Detorsion of the pedicle and subsequent excision of the cyst was performed with preservation of the right ovary despite the necrotic aspect. The pathology findings were paratubal serous paratubal cyst.

The patient evolved favorably and was evaluated at her next menstrual period, and AFR was performed. Eight follicles were found in the right ovary and 10 follicles in the left ovary. Follicular follow-up was performed, showing ovulation and presence of corpus luteum in the right ovary. Due to her adequate ovarian reserve, she was proposed to enter the oocyte donation program. Antimüllerian hormone (AMH) was mea-

FIGURE 1. ADNEXAL CYST WITH A TWISTED PEDICLE INVOLVING THE IPSILATERAL OVARY.

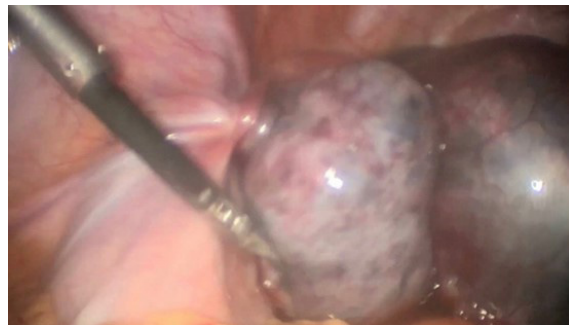

FIGURE 2. 12 OOCYTES FROM THE OVARY WITH A HISTORY OF PEDICLE TORSION.





sured with a value of 2.85 ng/mL, thyroid stimulating hormone (TSH) 1.8 mIU/L, prolactin 15 ng/mL.

Five months later she underwent controlled ovarian stimulation with rFSH 150 IU/day and ovulation inhibitor cetrorelix 0.25 mg/day. Triptorelin 0.2 mg was used to trigger ovulation and 36 hours later ovulation capture was performed.

Twenty-two oocytes were obtained: 12 oocytes from the right ovary (Figure 2), which had the history of torsion, and 10 oocytes from the left ovary. We found 14 mature oocytes (right ovary 8, left ovary 6) and 8 immature oocytes (Table 1).

DISCUSSION

Ovarian torsion involves rotation of the ovarian tissue in its pedicle leading to decreased venous return, stromal edema and internal hemorrhage that could lead to infarction. The risk of torsion increases when pelvic masses exceed 5 cm, as in the case presented, whose pelvic mass of more than 10 cm suffered torsion. Laparoscopy revealed a cystic tumor and a bluish-black ipsilateral ovary. Many recent studies support detorsion without oophorectomy as the treatment of choice for adnexal torsion⁽⁸⁾. Balasubramaniam⁽⁶⁾ and Dasgupta⁽⁹⁾ found recovery of ovarian function in post-surgical controls when assessing AFR ultrasonographically and measuring AMH levels. Therefore, in our case it was decided to conserve the ovary and perform only cystectomy, later showing the recovery of ovarian function by ultrasound.

The edematous, ischemic-hemorrhagic appearance of the adnexa does not necessarily indicate necrosis. It is probably secondary to venous-lymphatic stasis, rather than gangrene. Chu recom-

mends conservative management even if the adnexa remain twisted for more than 7 hours⁽¹⁰⁾. In the case presented, the pain increased and was associated with nausea 4 hours before admission, supporting conservative surgery. Once detorsion was performed, the color of the ovarian tissue did not fully recover. However, based on different studies, it was decided to keep the ovary. Chu states that the improvement in color indicates reestablishment of irrigation and preservation of the ovarian tissue. Even if there is no immediate change to normal color in the twisted adnexa, conservative management should not be ruled out⁽¹⁰⁾.

Adnexectomy is still used today for the management of adnexal torsion because of the fear that uncoiling of the ovarian pedicle may lead to a thromboembolic event. Since conservative management of adnexal torsion by laparoscopy was first described in 1990⁽¹⁰⁾, several other reports have described successful management with the same technique⁽⁶⁾. A review of the literature showed that none of the 309 patients undergoing conservative surgery showed a thromboembolic event, while two cases of thromboembolism followed 672 adnexectomies. Subsequently, two large retrospective series showed no thromboembolic events in case of detorsion, further supporting the conservative approach⁽¹⁰⁾.

In patients with post detorsional genic desires it is recommended to evaluate ovarian function by AFR and AMH. Yasa found that at 3 months after surgery there was no difference in the average AFR between the operated and contralateral sides⁽⁸⁾. In our case, the patient had adequate AFR and AMH and she was included in the oocyte donation program. An adequate ovarian reserve was observed with the extraction of 22 oocytes, 12 of which were from the previously affected ovary, and of these, 8 mature oocytes. That is to say, there was an adequate ovarian reserve in quantity and quality for her age.

Therefore, with no infections, no adhesions and no malignant problems, conservative surgery for the management of adnexal torsion should be considered whenever fertility is desired despite the appearance of the ovary. In most cases, the ovary will regain perfusion and remain viable.

TABLE 1. CLASSIFICATION OF OOCYTES OBTAINED ACCORDING TO OVARY.

Oocyte phase	Ovary		Total
	Right (history of pedicle torsion)	Left	
Metaphase 2	8	6	14
Metaphase 1	0	1	1
Germinal vesicle	4	3	7
Total	12	10	22



REFERENCES

1. Leon MG, Carrubba AR, Robertson M, Dinh TA. 79: Avoiding oophorectomy in acute ovarian torsion. *Am J Obstet Gynecol*. 2020 Mar;222(3):S859. DOI:<https://doi.org/10.1016/j.ajog.2019.12.228>
2. ACOG Committee Opinion No 783. Adnexal Torsion in Adolescents. *Obstet Gynecol* [Internet]. 2019 Aug;134(2):e56–63. Doi: 10.1097/AOG.0000000000003373
3. Mounika P, Ratnakumari, Sreelatha. Left adnexal torsion in adolescent: a case report. *Int J Adv Res*. 2022 May 30;10(05):21–4. DOI: <http://dx.doi.org/10.21474/IJAR01/14671>
4. Aviles Alepuz B, Ramón Fernández F. La donación de óvulos en la reproducción asistida: riesgos y responsabilidad. *IUS Sci*. 2019;5(2):11–54. DOI: <http://doi.org/10.12795/IESTSCIEN-TIA.2019.i02.03>
5. Committee of the American Society for Reproductive Medicine and the Practice Committee for the Society for Assisted Reproductive Technology. Guidance regarding gamete and embryo donation. *Fertil Steril*. 2021 Jun;115(6):1395–410. DOI: <https://doi.org/10.1016/j.fertnstert.2021.01.045>
6. Balasubramaniam D, Duraisamy K, Ezhilmani M. Laparoscopic detorsion and fertility preservation in twisted ischemic adnexa – A single-center prospective study. *Gynecol Minim Invasive Ther*. 2020;9(1):24. DOI: 10.4103/GMIT.GMIT_20_19
7. Asfour V, Polson A, Varma R, Menon P. Evaluating ovarian preservation after ovarian torsion using the ovarian preservation score and tissue necrosis score. *Clin Obstet Gynecol Reprod Med*. 2015;1(2):34–9. DOI:10.15761/COGRM.1000110
8. Yasa C, Dural O, Bastu E, Zorlu M, Demir O, Ugurlucan FG. Impact of laparoscopic ovarian detorsion on ovarian reserve. *J Obstet Gynaecol Res*. 2017 Feb;43(2):298–302. <https://doi.org/10.1111/jog.13195>
9. Dasgupta R, Renaud E, Goldin AB, Baird R, Cameron DB, Arnold MA, et al. Ovarian torsion in pediatric and adolescent patients: A systematic review. *J Pediatr Surg*. 2018 Jul;53(7):1387–91. <https://doi.org/10.1016/j.jpedsurg.2017.10.053>
10. Chu K, Zhang Q, Sun N, Ding H, Li W. Conservative laparoscopic management of adnexal torsion based on a 17-year follow-up experience. *J Int Med Res*. 2018 Apr 27;46(4):1685–9. <https://doi.org/10.1177/0300060517754025>