

CASE REPORT

1. Staff Physician, Instituto Peruano de Medicina y Cirugía Fetal, Lima, Peru
2. Staff Physician, Maternal Fetal Medicine Unit, Clínica Delgado AUNA, Lima, Peru
a. <https://orcid.org/0000-0001-6515-2599>

Conflicts of interest: None.

Funding source: Self-funded.

Received: 20 July 2022

Accepted: 8 August 2022

Online publication: 12 September 2022

Corresponding author:

Dr. Enrique Gil Guevara

📍 Calle Enrique Palacios 360, Miraflores
Instituto Peruano de Medicina y Cirugía Fetal, Lima, Perú

☎ +51 987248251

✉ enrique.gil@doctors.org.uk

Cite as: Gil Guevara E, Muñoz Acosta J, Marchena Arias J, Gonzales O, Acuña L, Chang C, Miranda B. Fetoscopic surgery in amniotic band syndrome: report of the first successful case in Peru with postnatal outcome at 6 and 12 months of life. *Rev peru ginecol obstet.* 2022;68(3). DOI: <https://doi.org/10.31403/rpgo.v68i2433>

Fetoscopic surgery in amniotic band syndrome: report of the first successful case in Peru with postnatal correlation at 6 and 12 months of life

Cirugía fetoscópica en síndrome de banda amniótica: comunicación del primer caso exitoso en el Perú con correlación posnatal a los 6 y 12 meses de vida

Enrique Gil Guevara^{1,2,a}, Jairo Muñoz Acosta¹, Jeannette Marchena Arias², Oswaldo Gonzales^{1,2}, Leopoldo Acuña², Carolina Chang², Braowell Miranda²

DOI: <https://doi.org/10.31403/rpgo.v68i2433>

ABSTRACT

Amniotic band syndrome (ABS) or amniotic band disruption complex is a congenital malformation that occurs because of amniotic flanges of heterogeneous etiology, a pathogenesis that involves a series of fetal clinical manifestations, such as constriction, amputation, and multiple craniofacial, visceral and wall defects. The estimated prevalence of ABS ranges from 1:15,000 to 1:1,200 liveborn. It affects both sexes equally. Prenatal diagnosis may be suspected as early as the late first trimester when ultrasound imaging detects constriction rings, limb amputations and/or craniofacial defects. Prenatal therapy may offer an alternative treatment with release of constriction rings through fetoscopy in those fetuses that would benefit from the procedure.

Key words: Amniotic band syndrome, Amputation, Laceration, Fetus, Video-assisted surgery

RESUMEN

El síndrome de banda amniótica (SBA) o complejo de disrupción de banda amniótica es aquella malformación congénita que ocurre como consecuencia de bridas amnióticas de etiología heterogénea, patogénesis que involucra una serie de manifestaciones clínicas fetales, tales como constricción, amputación y múltiples defectos craneofaciales, viscerales y de la pared del cuerpo. La prevalencia estimada de SBA oscila entre 1:15,000 y 1:1,200 nacidos vivos. Afecta a ambos sexos por igual. El diagnóstico prenatal puede sospecharse tan pronto como el primer trimestre tardío, cuando las imágenes por ultrasonido detectan anillos de constricción, amputaciones de extremidades y/o defectos craneofaciales. La terapia prenatal puede ofrecer una alternativa de tratamiento con la liberación de anillos de constricción bajo fetoscopia en aquellos fetos que se verían beneficiados con el procedimiento.

Palabras clave: Síndrome de banda amniótica, Amputación, Laceración, Feto, Cirugía asistida por vídeo

INTRODUCTION

Amniotic band syndrome (ABS) or amniotic band disruption complex is a congenital malformation that occurs in association with amniotic flanges of heterogeneous etiology. It involves a series of fetal clinical manifestations such as constriction, amputation and multiple craniofacial, visceral and body wall defects, which produce sequelae of great limitation in the functionalism of the compromised structures.

There are theories that try to explain the genesis of amniotic bands, and it is believed that the main mechanism is the rupture of the amnion in early pregnancy, which results in the development of multiple loose mesodermal strands on the chorionic side of the amnion that adhere and/or entangle the embryo⁽¹⁾.



Timely ultrasound diagnosis is the cornerstone of the management of this entity, in which a healthy fetus is susceptible to damage by amniotic constriction. Based on advances in fetal therapy, an alternative treatment can be offered with the release of constriction rings under fetoscopy.

The estimated prevalence of ABS ranges from 1:15.000 to 1:1.200 live births. It affects both sexes equally⁽²⁾. Regarding risk factors, smoking and residence at high altitude have been described. However, there are no consistent studies to establish risk factors with precision^(3,4).

The etiology of amniotic band formation is not known with certainty⁽⁵⁾. Some authors propose that either a primary defect or an early disruption of the amnion, these bands occur during the production of the mesodermal matrix. Others have proposed that ischemic events lead to the development of the bands⁽⁶⁾. Several theories have been put forward with the intention of explaining the etiopathogenesis, currently the most accepted are the intrinsic and extrinsic theories⁽⁷⁾.

In 1930, Streeter postulated the intrinsic theory which maintains that the amniotic band syndrome represents an inherent defect in the embryogenic development due to a defect in the differentiation of the germinative plasma, which would form the fibrotic bands that cause a necrotic limb.

Torpin, in 1965, proposed that rupture of the amniotic membrane and its detachment from the chorion lead to the fetus emerging from the amniotic cavity. Natural healing of the defective amnion and bare chorion results in the formation of adhesions that can trap various fetal organs, leading to constriction and amputations; this theory is the extrinsic theory.

Prenatal diagnosis may be suspected as early as the late first trimester⁽⁸⁾, when ultrasound imaging detects constriction rings, limb amputations and/or lateralization of the body wall or craniofacial defects that are normally midline⁽⁹⁾.

In cases where there is no limb amputation, constriction rings can be observed.

It is important during the ultrasound examination to closely observe fetal movements, as well

as the relief of body surfaces such as the back or the thoraco-abdominal wall. Likewise, stimulating the fetus with the ultrasound transducer can reveal amniotic bands that are not easily visible, identifying them as fine undulating strands that restrict its movement⁽¹⁰⁾.

Regarding three-dimensional prenatal ultrasound or magnetic resonance imaging (MRI), these are techniques that can provide more detailed information about the anomalies and thus aid in the diagnosis or establish a differential diagnosis. On T2-weighted MRI images, amniotic bands can be seen as thin strands⁽¹¹⁾.

Visualization of the amnion before 16 weeks of gestation without fetal structural abnormalities should not be confused with amniotic banding, since the amnion does not fuse with the chorion until approximately 16 weeks of gestational age⁽¹²⁾.

The differential diagnosis of amniotic band syndrome is primarily with uterine synechiae. Uterine synechiae are thicker than bands, often have a broad triangular base along the uterine wall, may extend to the contralateral wall, and there is usually a history of uterine curettage in the maternal history⁽¹³⁾.

The chorioamniotic separation may be mistaken for an amniotic band, but the curvature of the amnion is often crescent-shaped and reflects the contour of the chorion⁽¹⁴⁾.

Once the diagnosis of ABS is made, the prenatal Doppler study of the affected structure, comparing it with the flow of the contralateral limb, represents an indispensable resource in the follow-up of this finding⁽¹⁵⁾, since the natural evolution of the limb affected by ABS is characterized by the progression of distal edema to amputation of the limb secondary to vascular insufficiency⁽¹⁶⁾.

The release of amniotic bands by fetoscopy makes it possible to preserve the life of the fetus or to avoid amputation of a limb and preserve its mobility in 50% of affected fetuses⁽¹⁷⁾.

There are currently two techniques described to free the amniotic bands, either using a diode or neodymium YAG laser fiber, or with the use of optical scissors. It may even be necessary to use both tools during the same procedure.



There are not many records of fetoscopic surgery to release amniotic bands. A review of the literature included 27 cases of fetoscopic lysis of amniotic bands using laser (12 cases), scissors (6 cases) or both (5 cases). The procedures were performed between 21 and 26 weeks of gestation. Outcome was available in 25 cases and included a functional limb in 17 cases (68%), limited mobility in 7 cases (28%) and limb amputation in 1 case (4%). In addition, 5 pregnancies (20%) developed preterm premature rupture of membranes before 32 weeks and 16 patients (64%) delivered preterm before 37 weeks' gestation⁽¹⁸⁾.

CASE REPORT

The case is presented with parental consent for its description and publication of images, as well as information on postnatal results.

This is a 23-year-old primigestation with no clinically significant personal pathological history and a first trimester genetic ultrasound scan reported as normal.

The second trimester morphological ultrasound was performed at 22 weeks of gestation. The findings were as follows: single female fetus in longitudinal position, cephalic presentation, without free movement, in a vicious position, with a thin undulating echogenic image bordering the fetal body surface (figure 1), as well as a constriction ring at lumbar level, which circumferentially surrounded the fetal abdomen (figure 2). The lower limb was in a vicious position, immobile, with a constriction ring at the ankle level, causing edema of the most distal portion of the limb and decreased Doppler flow in relation to the contralateral limb, as well as ultrasound signs suggestive of green stem fracture in that region (Figure 3). No major structural malformations or sonographic markers of aneuploidy were evident. Also, fetal growth and amniotic fluid were normal.

The diagnosis of ABS and the natural history of the disease, including imminent amputation of the affected lower limb, as well as the risks and benefits of prenatal surgery, were explained to the parents.

Under informed consent of the parents, it was decided to perform amniotic band lysis with minimally invasive technique under direct visualization by fetoscopy.

The surgery was performed at 23 weeks of gestation. After regional maternal anesthesia in the operating room, asepsis of the anterior abdominal wall was performed with 2% chlorhexidine, including the upper third of the lower limbs and the lower edge of the breasts. The bladder was evacuated with a Nelaton catheter, sterile fields were placed, and the ultrasound machine, fetoscope and fiber optics were assembled with white, horizon and sharpness verification. The entry point was chosen in the avascular zone of the abdominal and uterine wall, applying local

FIGURE 1. WAVE-LIKE ECHOGENIC IMAGE BORDERING THE FETAL STRUCTURE: AMNIOTIC BAND.

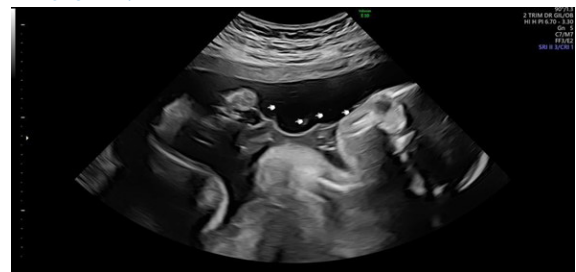

FIGURE 2. YELLOW ARROW INDICATES CONSTRICTION RING AT LUMBAR LEVEL SURROUNDING THE ABDOMINAL PERIMETER CAUSED BY AMNIOTIC BANDING.

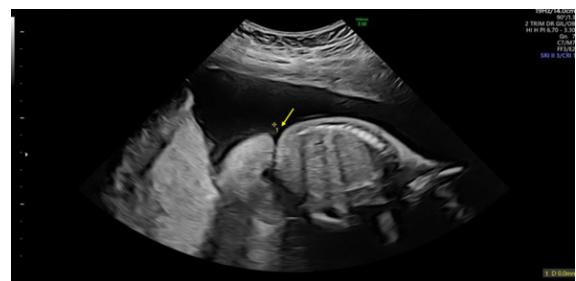
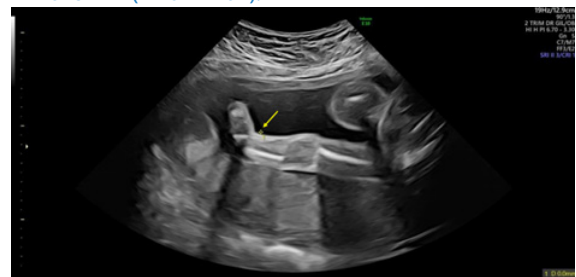

FIGURE 3. GRAY SCALE ULTRASOUND IMAGE SHOWING LOWER LIMB IN VICIOUS POSITION WITHOUT MOVEMENT, WITH CONSTRICTION RING BY AMNIOTIC BAND (YELLOW ARROW).





anesthesia with infiltration of the skin, abdominal wall, aponeurosis and myometrium, using 10 mL of 2% lidocaine without epinephrine.

A 3-mm skin incision was made with an 11-blade scalpel and then, under continuous ultrasound guidance, a 10 French caliber Check-Flo cannula (Cook Medical®) was introduced directly with a metal punch as a mandrel.

After removing the metal guidewire, the straight, integrated, semi-rigid 9.2 French caliber Karl Storz® brand fetoscope was introduced through the Check-Flo cannula, after which the amniotic cavity and fetal structures were systematically explored, locating the constriction rings (Figures 3 and 4).

The amniotic bands were released using a Karl Storz® brand fetoscopic grasper (Figure 5) both at the level of the right leg and the abdomen in the lumbar area.

After 20 minutes of fetal surgery and under ultrasound guidance, the fetoscope was removed, the Check-Flo cannula was withdrawn and a skin stitch was placed with nylon 00 suture. Ultrasonographically, regular fetal cardiac activity was verified, the case was reevaluated the following day and medical discharge with antibiotic prophylaxis was indicated.

In the post-surgical control, a control ultrasound evaluation was performed 7 days after surgery, with the following findings: single active gestation of 24 weeks of gestation with fetus in longitudinal position and free body and limb movements.

FIGURE 4. FETOSCOPIC IMAGE OF THE DISTAL THIRD OF THE TRAPPED LOWER LIMB WITH CONSTRICTION RING BY AMNIOTIC BAND (YELLOW ARROW). NOTE THE DIFFERENCE IN VASCULARITY ON BOTH SIDES OF THE CONSTRICTION RING WITH EDEMA AND PLETHORIC VASCULARITY AT THE DISTAL END (BLUE ARROW).

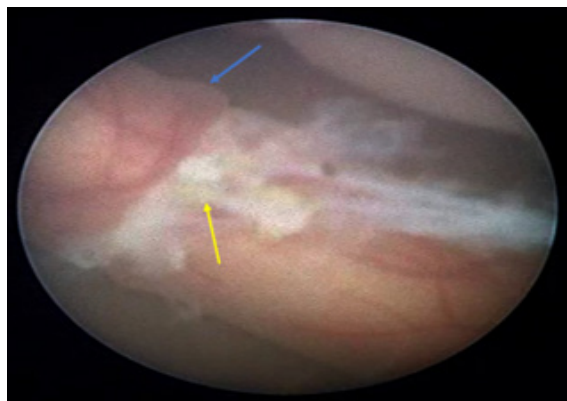
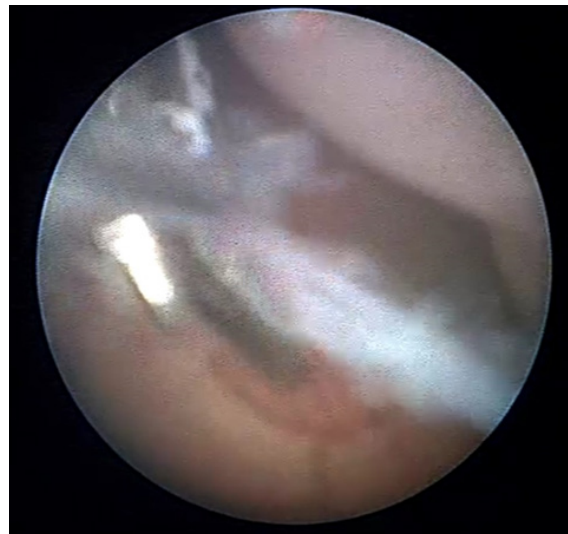

FIGURE 5. RELEASE OF THE AMNIOTIC BAND CONSTRICTION RING WITH FETOSCOPIC GRASPER.



There was no constriction ring in the lumbar region or in the abdomen (Figure 6).

The right lower limb presented free movements, without constriction ring, although the image suggestive of tibia fracture in green stem persisted (Figure 7).

FIGURE 6. POST-SURGICAL ULTRASOUND CONTROL; THE SAGITTAL SECTION OF THE SPINE SHOWS THE ABSENCE OF THE CONSTRICTION RING DUE TO THE AMNIOTIC BAND.

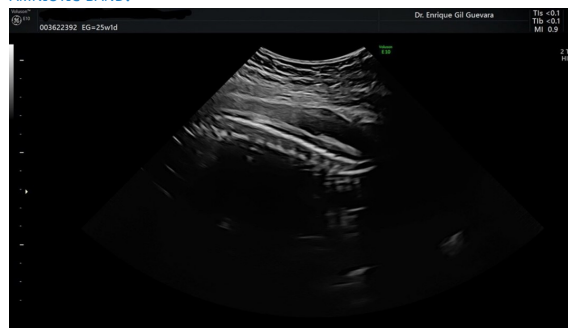
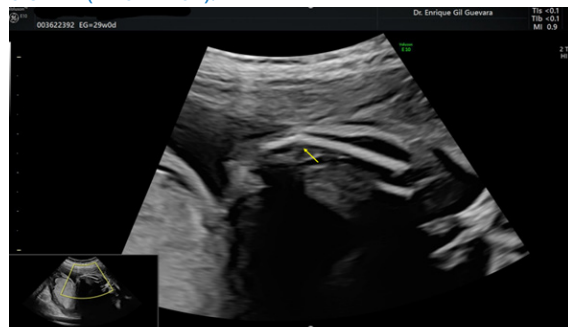
FIGURE 7. POST-SURGICAL ULTRASOUND CONTROL; THE ABSENCE OF THE CONSTRICTION RING IN THE LOWER LIMB WITH RESIDUAL BONE DEFORMITY IS OBSERVED (YELLOW ARROW).





The placenta was in the posterior wall and high with respect to the internal cervical os, without ultrasound data of placental abruption or shortening of the cervix. Likewise, the amniotic fluid was normal.

At 32 weeks of gestation, the patient presented premature rupture of membranes, for which she went to the emergency room of a tertiary hospital.

On physical examination, maternal and fetal vital functions were stable; there was no evidence of uterine dynamics or cervical changes, and loss of clear amniotic fluid was corroborated. Antibiotic therapy and fetal lung maturation were indicated.

In the following hours, the patient presented persistent uterine dynamics, so continuous electronic fetal monitoring was started and recurrent decelerations of the fetal heart rate were observed, so it was decided to perform an emergency cesarean section.

The findings were a live female newborn (NB), weighing 1,615 grams, height 41 cm, Apgar 7-8, showing a solution of continuity at the abdominal level and deformity in the right lower limb (Figure 8).

Hospitalization in neonatal intermediate care was decided with the diagnoses of 32 weeks preterm newborn, probable fracture of the right leg and abdominal continuity solution due to sequelae of ABS in the process of closure and re-epithelialization. The following day the results of the chest X-rays were available, in which no parenchymal infiltrates were observed. The

FIGURE 8. NEONATAL CONTROL, SHOWING THE MARK ON THE SKIN OF THE LOWER LIMB WITH RESIDUAL BONE DEFORMITY.



X-ray of the lower limbs showed no evidence of fracture, but did show deformity (arching at the level of the distal third of the right lower limb).

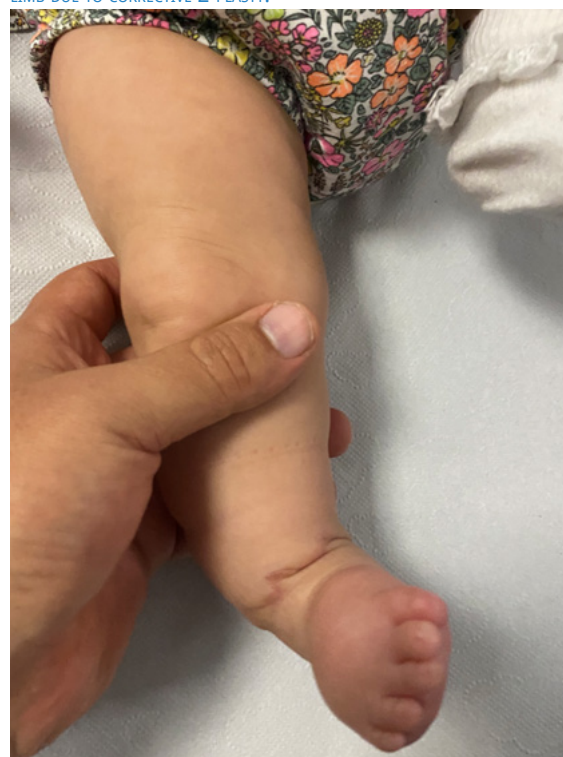The evolution was favorable and neonatal discharge was decided at 23 days of age, weight 1,926 grams and height 42 cm.

At three months of age, the baby underwent three Z-plasty plastic surgeries in a specialized clinic, both in the right leg (circular incision) and on the abdomen on each side of the amniotic constriction zone. This technique has been the most popular technique in postnatal reconstructive plastic surgery, especially those with circular incisions, because it has many advantages, including the reduction of surgical invasiveness, scar formation and the cost of treatment.

At six months of age, her growth and psychomotor development checks were normal, with marked improvement of the scar area on the leg (Figure 9) and abdominal circumference.

At 12 months of age, she underwent a final Z-plasty type plastic surgery at the abdominal level, the evolution of which was favorable, as well as her general growth and psychomotor development.

FIGURE 9. POSTNATAL CONTROL: SCAR IS VISUALIZED IN THE RIGHT LOWER LIMB DUE TO CORRECTIVE Z-PLASTY.





DISCUSSION

The present case represents an important achievement in the history of Peruvian fetal surgery for demonstrating that ABS, despite being a mutilating and lethal pathology, can be diagnosed and treated in a timely manner in our country, obtaining a favorable postnatal outcome at 6 and 12 months of age.

Based on what has been published, we believe that timely management by fetoscopic release of the constriction rings in the ABS, before severe progressive vascular compromise occurs, can restore normal perfusion and prevent amputation of the affected limb, as well as severe laceration of the compromised fetal body area.

Therefore, all patients diagnosed with ABS should be evaluated at a referral center in fetal medicine and surgery to assess those fetuses that may benefit from prenatal intervention, always considering the risks of performing it, mainly related to premature delivery.

In the present case, the release was performed using a fetoscopic forceps (grasper) introduced through a fetoscope with integrated optics, in the bands of free movement in the amnion and in those that were fixed to the fetal body.

Likewise, the participation of specialists in pediatric orthopedics and pediatric plastic surgery is essential, since 50% of these fetuses will require postnatal reconstructive and/or functional surgery, as occurred in the present case.

REFERENCES

1. Stevenson RE, Hall JG (Eds). *Malformaciones humanas y anomalías relacionadas*. 2° ed. Oxford: Oxford University Press, 2006:871.
2. Orioli IM, Ribeiro MG, Castilla EE. Clinical and epidemiological studies of amniotic deformity, adhesion, and mutilation (ADAM) sequence in a South American (ECLAMC) population. *Am J Med Genet A*. 2003 Apr 15;118A(2):135-45. doi: 10.1002/ajmg.a.10194. PMID: 12655494
3. Lowry RB, Bedard T, Sibbald B. The prevalence of amnion rupture sequence, limb body wall defects and body wall defects in Alberta 1980-2012 with a review of risk factors and familial cases. *Am J Med Genet A*. 2017 Feb;173(2):299-308. doi: 10.1002/ajmg.a.38016. Epub 2016 Oct 14. PMID: 27739257
4. Richter J, Wergeland H, DeKoninck P, De Catte L, Deprest JA. Fetoscopic release of an amniotic band with risk of amputation: case report and review of the literature. *Fetal Diagn Ther*. 2012;31(2):134-7. doi:10.1159/000335026
5. Sifakis S, Mantas N, Konstantinidou A, Koukoura O, Avgoustinakis E, Koumantakis E. A stillborn fetus with amniotic band syndrome and elevated levels of alpha-fetoprotein plus beta-human chorionic gonadotropin: a case report. *Fetal Diagn Ther*. 2008;24(2):111-4. doi: 10.1159/000142139
6. Da Silva G, Cammarata F, Gonzales M y cols. Síndrome de bridas amnióticas, caso clínico. *Rev Chil Pediatr*. 2008;79(2):172-80.
7. Diaz Primera RJ, Gil Guevara ED, Sánchez Jiménez R, Bermúdez González C. Cirugía fetal en bandas amnióticas. *Rev Peru Ginecol Obstet*. 2018;64(4):639-45. DOI: <https://doi.org/10.31403/rpgo.v64i2134>
8. Barzilay E, Harel Y, Haas J, Berkenstadt M, Katorza E, Achiron R, Gilboa Y. Prenatal diagnosis of amniotic band syndrome - risk factors and ultrasonic signs. *J Matern Fetal Neonatal Med*. 2015 Feb;28(3):281-3. doi: 10.3109/14767058.2014.915935. Epub 2014 May 22. PMID: 24735486
9. Jensen KK, Oh KY, Kennedy AM, Sohaey R. Intrauterine Linear Echogenicities in the Gravid Uterus: What Radiologists Should Know. *Radiographics*. 2018 Mar-Apr;38(2):642-57. doi: 10.1148/rg.2018170062
10. Neuman J, Calvo-Garcia MA, Kline-Fath BM, Bitters C, Merrow AC, Guimaraes CV, Lim FY. Prenatal imaging of amniotic band sequence: utility and role of fetal MRI as an adjunct to prenatal US. *Pediatr Radiol*. 2012 May;42(5):544-51. doi: 10.1007/s00247-011-2296-8. Epub 2011 Dec 2. PMID: 22134536
11. Burton DJ, Filly RA. Sonographic diagnosis of the amniotic band syndrome. *AJR Am J Roentgenol*. 1991 Mar;156(3):555-8. doi: 10.2214/ajr.156.3.1899757
12. Randel SB, Filly RA, Callen PW, Anderson RL, Golbus MS. Amniotic sheets. *Radiology*. 1988 Mar;166(3):633-6. doi: 10.1148/radiology.166.3.3277238
13. Holmes LB, Westgate MN, Nasri H, Toufaily MH. Malformations attributed to the process of vascular disruption. *Birth Defects Res*. 2018 Jan;110(2):98-107. doi: 10.1002/bdr2.1160. PMID: 29377641
14. Nardoza LM, Araujo Júnior E, Caetano AC, Moron AF. Prenatal diagnosis of amniotic band syndrome in the third trimester of pregnancy using 3D ultrasound. *J Clin Imaging Sci*. 2012;2:22. doi: 10.4103/2156-7514.95436
15. Belfort MA, Whitehead WE, Ball R, Silver R, Shamshirsaz A, Ruano R, Espinoza J, Becker J, Olutoye O, Hollier L. Fetoscopic amniotic band release in a case of chorioamniotic separation: An innovative new technique. *AJP Rep*. 2016 Apr;6(2):e222-5. doi: 10.1055/s-0036-1579538
16. Minella C, Costantino B, Ruano R, Koch A, Weingartner AS, Favre R, Sananes N. Fetoscopic Release of Amniotic Band Syndrome: An Update. *J Ultrasound Med*. 2021 May;40(5):1039-48. doi: 10.1002/jum.15480
17. Crombleholme TM, Dirkes K, Whitney TM, Alman B, Garmel S, Connelly RJ. Amniotic band syndrome in fetal lambs. I: Fetoscopic release and morphometric outcome. *J Pediatr Surg*. 1995 Jul;30(7):974-8.
18. Quintero RA, Morales WJ, Phillips J, Kalter CS, Angel JL. In utero lysis of amniotic bands. *Ultrasound Obstet Gynecol*. 1997 Nov;10(5):316.