

ORIGINAL PAPER

1. Adjunt Physician Gynecology and Obstetrics Service, Hospital Universitari Parc Taulí, Parc Taulí I3PT Innovation and Research Institute, Universidad Autónoma de Barcelona, Sabadell (08208), Spain
2. Associate Professor Universitat Autònoma de Barcelona (UAB), Hospital Universitari Parc Taulí, Sabadell (08208), Spain

The authors of this article manifest the following:

The manuscript was remitted exclusively to the Revista Peruana de Ginecología y Obstetricia. It is not being considered in any other publication and it has not been previously published

The authors are responsible for the investigation and have participated in its concept, design, analysis and interpretation of the data, writing and editing of the manuscript, as in the definite approved version which has been sent

The authors affirm they got the consent of the institution and of the objects of the study through a specific informed consent form. The project has been authorized by the Ethics Committee of the Hospital

The authors notify no conflict of interests in relation to their manuscript

Ethical aspects

There are no ethical conflicts. This study does not identify the individual, guaranteeing the confidentiality of their data. The data is dissociated in order to collect it in a totally anonymous way. Investigators declare no conflicts of interest. Researchers state that there has been no financial benefit from the promoter or any external entity in connection with the study conducted.

Received: 29 April 2020

Accepted: 11 May 2020

Correspondence:

Yulieth Estephany Martínez Meza

📍 Calle 48 N # 5-24

✉ yemartinezm@hotmail.com

Citar como: Vilà Famada A, Pina Pérez S, Jurado Seguer J, Lleberia Juanos J, Costa Pueyo J. Validation of IOTA ultrasound criteria in clinical practice with tumor markers and pathology. Rev Peru Ginecol Obstet. 2020;66(3). DOI: <https://doi.org/10.31403/rpgov.v66i2262>

Validation of IOTA simple ultrasound rules in clinical practice with tumor markers and pathology

Validación de los criterios ecográficos IOTA en la práctica clínica con marcadores tumorales y patología

Anna Vilà Famada¹, Silvia Pina Pérez^{1,2}, Judith Jurado Seguer¹, Judith Lleberia Juanos^{1,2}, Jordi Costa Pueyo^{1,2}

DOI: <https://doi.org/10.31403/rpgov.v66i2262>

ABSTRACT

Objectives: To determine correlation between preoperative ultrasound evaluation of adnexal masses applying IOTA simple rules and pathology diagnosis. To assess usefulness of biochemical tumor markers in these cases. **Methods:** A prospective study was performed between January 2017 and February 2020. Patients with suspected ovarian pathology were evaluated using IOTA ultrasound rules and designated as benign or malignant. Findings were correlated with histopathological findings. Collected data was statistically analyzed using the chi-square test and kappa statistical method. **Results:** During this period, 102 women were eligible for the study. According to IOTA ultrasound criteria, 48% of the adnexal masses were classified as benign, 24.5% malignant and 27.5% were not classifiable. Pathology confirmed 68.1% of benign and 72.8% of malignant tumors were correctly classified by ultrasound. Statistically, the agreement between pre-surgical transvaginal ultrasound and pathology result was significant with contingency coefficient 0.58 and Kappa index 0.47, both with $p < 0.05$ significance. The sensitivity for detection of malignancy with IOTA simple rules was 94.1% and specificity 92.1%. As for biochemical tumor markers, human epididymal protein 4 (HE4) and cancer antigen 125 (CA 125) values had statistically significant correlation with pathology results. **Conclusions:** IOTA simple rules may be used in clinical practice for diagnosis of ovarian tumors. Human epididymis 4 appeared a better diagnostic tool than CA 125 in discrimination of malignant adnexal masses.

Key words: Ovarian cysts, Ovarian neoplasms, Ultrasonography, Biomarkers, tumor.

RESUMEN

Objetivos. Correlacionar la ecografía prequirúrgica de las masas anexiales aplicando los criterios IOTA y el diagnóstico anatomopatológico tras intervención quirúrgica. Valorar la utilidad de los marcadores tumorales bioquímicos. **Método.** Estudio observacional prospectivo en 102 pacientes con diagnóstico ecográfico de tumoración anexial, intervenidas quirúrgicamente entre enero 2017 y febrero 2020. El análisis estadístico se realizó con SPSS 17.0. Las variables categóricas se analizaron mediante pruebas de Fisher y chi-cuadrado, las variables cuantitativas mediante prueba t-student. La concordancia entre la valoración de la ecografía transvaginal mediante criterios IOTA y el resultado anatomopatológico, se estudió con el coeficiente de contingencia y el índice kappa. **Resultados.** Según criterios IOTA, se clasificó como benignas a 48% de las tumoraciones, como malignas 24,5%, y 27,5% resultaron no clasificables. La anatomía patológica confirmó que 68,1% de las benignas y 72,8% de las malignas fueron correctamente filiadas por la ecografía. La concordancia entre la ecografía transvaginal prequirúrgica y la anatomía patológica fue significativa, con coeficiente de contingencia 0,58, índice kappa 0,47, $p < 0,05$ y con sensibilidad 94,1% y especificidad 92,1%. Los valores de la proteína epididimal humana 4 (HE4) y el antígeno del cáncer 125 (CA 125) tuvieron correlación con la anatomía patológica, también con significación estadística, siendo mayor en las pacientes menopáusicas. **Conclusiones.** Los criterios IOTA discriminaron de forma satisfactoria las masas benignas de las malignas. La proteína HE4 resultó mejor marcador bioquímico que el CA125.

Palabras clave. Quistes ováricos, Cáncer de ovario, Ecografía, Biomarcadores, tumor.

INTRODUCTION

Adnexal masses are a frequent reason for consultation in gynecology and morphological evaluation using pelvic ultrasound is the first study to be performed. An ultrasound is an easily executable, repeatable, relatively low-cost procedure, and remains the method of choice for distinguishing between benign and malignant adnexal pathologies. By



identifying patterns, several types of tumors can be classified according to their characteristic appearance in grayscale images. Proper characterization of adnexal masses is a critical step in planning the right therapeutic approach.

Different studies report that up to 90% of ovarian masses can⁰ be correctly classified as benign or possibly malignant by an expert sonographer, and thus determine the need for surgery, the type of surgical procedure and its priority.

Several risk-prediction models have been⁰ proposed, to⁰ differentiate adnexal masses, which evaluate tumors and classify risk according to the following ultrasound findings: multilocularity, presence of solid areas, bi-laterality, ascites, evidence of metastasis, menopausal status and different biochemical markers. Such models can be complex and difficult to apply in standard clinical practice. Several working groups arose from these complexities, such as the International Ovarian Tumor Analysis (IOTA)⁽⁴⁻⁶⁾, which was validated prospectively and externally. This group's aim was to reach an agreement in relation to ultrasound examinations and its terminology. This consensus of the IOTA group describes the ultrasound characteristics of adnexal tumors and estimates the possible risk of malignancy, in order to create standardized terms and definitions. The main aim is to help less experienced sonographers reproduce the good results of expert sonographers. In addition, the combination of the ultrasound study with biochemical markers (CA125 or HE4) seems to be even more sensitive to classifying the malignancy of the lesion⁽⁷⁻⁹⁾.

Our study aimed to assess the clinical applicability of the IOTA model, based on simple ultrasound criteria of classification of adnexal masses in terms of benignity or malignancy, prior to surgical intervention, as well as determining the sensitivity and specificity of said ultrasound assessment and the impact of biochemical markers on decision-making.

METHODS

A prospective observational study was carried out in the Ultrasound Unit of the Hospital Universitari Parc Taulí de Sabadell, which included a total of 102 patients with ultrasound diagnosis of adnexal tumors, to which the IOTA criteria were applied and that were surgically intervened between January 2017 and February 2020.

The methodology of the IOTA criteria includes the division of ultrasound findings into two characteristic groups: rules B and rules M (Figure 1). The B rules for predicting a benign tumor consist of the following characteristics: unilocular masses, presence of solid components with a diameter larger than <7 mm, presence of acoustic shadow, multilocular smooth tumor with a diameter larger than <100 mm and no blood flow. M rules for predicting malignant lesion include irregular solid tumor, presence of ascites, at least four papillary structures, irregular multilocular solid tumor with a diameter larger than 100 mm, and an abundant blood flow. If one or more M-rules are applied in the absence of a rule B, a mass is predicted as malignant. If one or more B-rules apply in the absence of an M rule, a mass is predicted as benign. If rules M and rules B apply or no rule applies, the mass is classified as inconclusive.

Thus, the adnexal tumors were classified as probably malignant, probably benign or unclassified following the simple rules of IOTA.

The ultrasound study was always with transvaginal access. In cases of tumors with IOTA criteria of malignancy, they were given an additional abdominal study to rule out possible ascites and to finish filling the adnexal mass. In none of these cases this additional abdominal study changed the initially performed transvaginal IOTA assessment. All ultrasound examinations were performed using a Voluson S8 ultrasound equipped with a 5-7.5 MHz endovaginal probe and a 3.5-5 MHz multifrequency convex transabdominal

FIGURE 1. IOTA ULTRASOUND CRITERIA.

5 ultrasound criteria of Benignity (B) and 5 of Malignancy (M) are assessed	
B1	Unilocular injury
B2	Solid component <7 mm
B3	Acoustic shadow
B4	Multilocular tumor >10 cm without solid areas
B5	Absent vascularity
M1	Solid tumor with irregular contours
M2	Ascites
M3	>4 papillary projections
M4	Multilocular tumor >10 cm with solid areas
M5	Abundant vascularity
Benign	>1 criterion of benignity, no criteria of malignancy
Malignant	>1 criterion of malignancy, no criteria of benignity
Not classifiable	No B or M criteria or criteria from both groups



probe. The lesions were classified as solid or liquid, unilocular or multilocular. After evaluation in mode B, Doppler was activated to evaluate tumor vascularity. The Doppler configuration was adjusted to achieve maximum sensitivity (frequency 5 MHz; dynamic range 20 to 40 dB; pulse repeat frequency 0.6 kHz). Central vascularity was defined in the presence of color spots within suspicious areas of the tumor such as thick papillary projections, solid areas or central part of solid tumors. Subsequently, presurgical IOTA staging was compared with histopathological results of the surgical specimens.

The four sonographers involved in this study performed all scans, with the informed consent of the patients.

The data was collected through the Microsoft Office Access 2000 program and previously analyzed using SPSS Statistics 17.0. The categorical variables were analyzed using Fisher's test and the chi-square test. The comparison of quantitative variables was performed with the t-student test. Statistical significance was defined as $p < 0.05$. The main study variable was the concordance between the assessment of transvaginal ultrasound using the IOTA criteria and the definitive pathology result, analyzed using the contingency coefficient and the Kappa index.

RESULTS

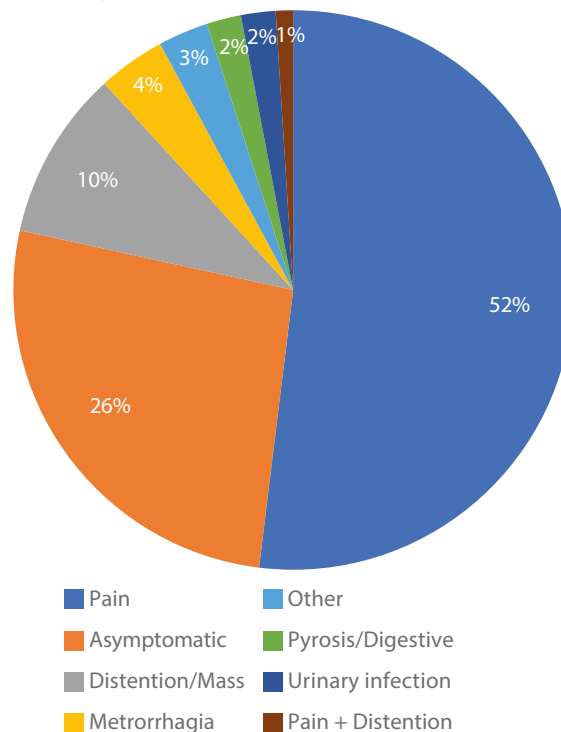
A total of 102 patients were included in this study. The average age in cases of benignity was 47.6 years and in cases of malignancy, 59 years, difference statistically significant. More than half of these patients (53.9%) were premenopausal.

The location of the tumor was one-sided in 94.1% of cases, 54.9% right and 39.2% left. In 6 cases it was bilateral (5.9%). 72.5% of the masses were regular, 66.7% unilocular, 12.7% bilocular and the remaining 20.6% multilocular.

In most patients, the first symptom was pain (52%), 26.5% of tumors were asymptomatic and 9.8% presented abdominal bloating as an initial symptom (Figure 2).

Based on the IOTA guidelines, 48% of adnexal masses were classified as benign lesions, 24.5% as malignant and 27.5% unclassifiable.

FIGURE 2. CLINIC OF THE ADNEXAL TUMOR STUDIED.



Biochemical tumor markers were also analyzed. We requested human epididymis protein 4 (HE4) in 57.8% of patients, cancer antigen 125 (CA 125) in 88.2% and carbohydrate antigen 19-9 (CA 19.9) in 73.5% of cases.

Other imaging tests, such as CT in 38.2% of patients and MRI in 16.9%, were needed.

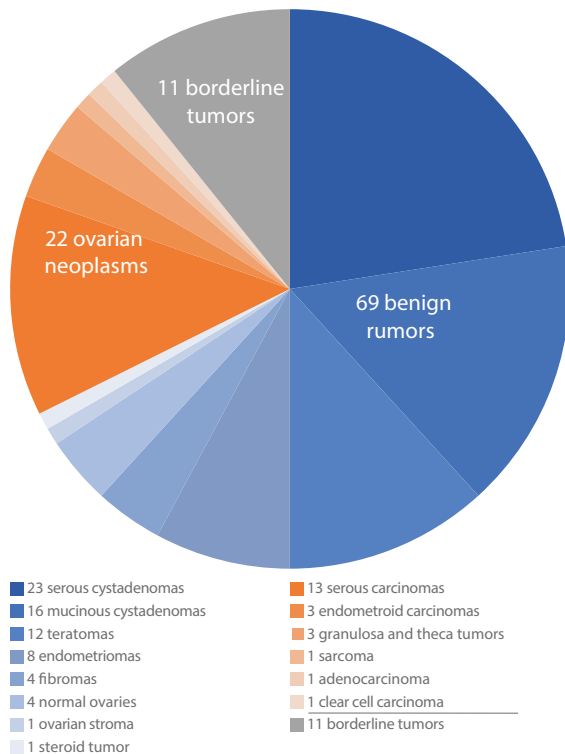
Surgical intervention was 98 \pm 11.9 days from the date of the ultrasound, unlike malignant tumors at 44.7 \pm 8.4 days, or borderline tumors at 45.1 \pm 16.9 days.

Out of the 102 adnexal tumors intervened, pathology reported 69 benign tumors, 22 neoplasms and 11 borderline tumors (Figure 3).

We observed a statistically significant relationship between pre-surgical transvaginal ultrasound and pathological anatomy (Figure 4), with a contingency coefficient of 0.58 and a kappa index of 0.47 ($p < 0.05$). 68.1% of benign masses reported by pathology were described as benign on ultrasound. Of the ovarian neoplasms, 72.8% were described as malignant on ultrasound. Finally, 45.5% of borderline tumors were listed as unclassified on ultrasound. Ultrasound sensitivity turned out to be 94.1% and specificity 92.1%.



FIGURE 3. PATHOLOGIC DIAGNOSIS OF ADNEXAL TUMORS.



with a positive likelihood ratio 12 and a negative 0.06. Also, the positive predictive value was 80% and the negative value was 97.9%.

Regarding biochemical tumor markers, human epididymis protein 4 (HE4) was studied in 59 patients (Figure 5). There were 10.1% false negatives (6/59) and 5% false positives (3/59), showing statistically significant relation with pathology findings and general contingency coefficient of 0.54, statistically significant. The contingency coefficient was not significant in the premenopausal group, 0.40, but statistically significant, 0.6, in the menopausal group.

FIGURE 4. CORRELATION BETWEEN TRANSVAGINAL ULTRASOUND EVALUATION BY IOTA CRITERIA AND PATHOLOGY FINAL RESULTS.

			Pathology results			Total
			Borderline	Benign	Malignant	
IOTA	Not classifiable	Count	5	18	5	28
		% within IOTA	17.9%	64.3%	17.9%	100.0%
	Benign	Count	1	47	1	49
		% within IOTA	2.0%	95.9%	2.0%	100.0%
	Malignant	Count	5	4	16	25
		% within IOTA	20.0%	16.0%	64.0%	100.0%
Total	Count	11	69	22	102	
	% within IOTA	10.8%	67.6%	21.6%	100.0%	

Cancer antigen 125 (Ca 125) was studied in 90 patients (Figure 5). There were 5.5% false negatives (5/90) and 10% false positives (9/90), with statistically significant relationship with pathology and general contingency coefficient of 0.49, statistically significant. In the premenopausal group, a non-significant contingency coefficient of 0,39 was observed, whereas a statistically significant contingency coefficient of 0.52 was obtained in menopausal patients.

Finally, the carbohydrate antigen 19-9 (Ca 19.9) was studied in 75 patients, with results not statistically significant for valuation of adnexal masses (Figure 5).

FIGURE 5. CORRELATION BETWEEN TUMOR MARKERS AND PATHOLOGY.

			Pathology results			Total
			Borderline	Benign	Malignant	
Pathological HE4	No	Count	4	16	4	24
		%	16.7%	66.7%	16.7%	100.0%
	Yes	Count	0	0	11	11
		%	0.0%	0.0%	100.0%	100.0%
Total		Count	4	16	15	35
		%	11.4%	45.7%	42.9%	100.0%
Pathological CA125	No	Count	3	20	3	26
		%	11.5%	76.9%	11.5%	100.0%
	Yes	Count	1	4	13	18
		%	5.6%	22.2%	72.2%	100.0%
Total		Count	4	24	16	44
		%	9.1%	54.5%	36.4%	100.0%
Pathological CA 19.9	No	Count	5	41	11	57
		%	8.8%	71.9%	19.3%	100.0%
	Yes	Count	4	8	5	17
		%	23.5%	47.1%	29.4%	100.0%
Total		Count	9	49	16	74
		%	12.2%	66.2%	21.6%	100.0%



DISCUSSION

In studies published previously, the simple ultrasound IOTA rules were not applied directly during the ultrasound exam. The ultrasound data was collected subsequently from the patients and evaluated according to prediction models⁽¹⁰⁻¹⁴⁾. Our study overcomes this limitation by directly applying simple IOTA ultrasound rules in patients. The literature describes the non-application of the IOTA (non-classifiable IOTA) criteria in about 10% of adnexal tumors. However, this percentage is higher in our case, since we have classified up to 27.5% of ultrasounds as IOTA unclassifiable. However, in most of these cases (64.3%), the definitive pathology was compatible with benignity. This is the main reason why 27% of ovarian neoplasms and 32% of benign tumors were not respectively catalogued as malign or benign, by ultrasound. This limitation arises from the application of a study in usual clinical practice, since not all masses show clearly predictive characteristics of benignity or malignancy.

Despite this comment, we consider that the ultrasound classification of adnexal tumors using IOTA criteria has proven to be highly sensitive and specific to predict ovarian malignancy prior to the surgery of the patient and, in general, prior to the design of a therapeutic strategy. Sensitivity, specificity, positive and negative likelihood ratio have been achieved, as well as positive and negative predictive value very similar to those described in the literature⁽¹⁵⁻¹⁷⁾ obtaining good concordance between this test and pathology.

As for the usefulness of biochemical tumor markers for the affiliation of adnexal masses, He4 has recently been proposed as an emerging biomarker in the differential diagnosis of adnexal masses and the early diagnosis of ovarian cancer⁽¹⁸⁻²¹⁾. We have individually analyzed each of the biochemical markers in each patient, also considering their age group. In this way we have concluded that both protein He4 and antigen Ca 125 have been useful in the assessment of adnexal tumors, providing more information in menopausal patients. He4 has been shown to be the most useful tumor marker, while Ca 19.9 did not provide additional information for handling of adnexal masses.

The limitation of this study is that of usual clinical practice, where the evaluation of non-classifiable masses using simple rules has been a challenge for researchers. More prospective and preferably randomized studies are needed to establish promising diagnostic tools, such as IOTA, with a positive influence for clinical management of the patient.

We conclude that most adnexal tumors may be correctly classified as benign or malignant using the IOTA classification. Tumor markers, mainly HE4 and also Ca 125, are useful in the preoperative diagnosis of ovarian malignancy, especially in menopausal women.

ACKNOWLEDGMENTS

To the service of Gynecology and Obstetrics, especially to the Ultrasound Unit of the Hospital Universitari Parc Taulí de Sabadell, for the follow-up of patients and the realization and notification of the IOTA criteria in all gynecological ultrasounds of adnexal masses.

REFERENCES

1. Sassone AM, Timor-Tritsch IE, Artner A, Westhoff C, Warren WB. Transvaginal sonographic characterization of ovarian disease: evaluation of a new scoring system to predict ovarian malignancy. *Obstet Gynecol.* 1991;78(1):70-6.
2. Meys EM, Kaijser J, Kruitwagen RF, Slangen BF, Van Calster B, Aertgeerts B, et al. Subjective assessment versus ultrasound models to diagnose ovarian cancer: A systematic review and meta-analysis. *Eur J Cancer.* 2016;58:17-29. doi:10.1016/j.ejca.2016.01.007
3. Li QL, Wang CJ, Qi P, Zhang YX. Correlation of preoperative ROMA scores with clinical stage in epithelial ovarian cancer patients. *Clin Transl Oncol.* 2017;19(10):1260-7. doi:10.1007/s12094-017-1664-8
4. Kaijser J, Bourne T, Valentin L, Sayasneh A, Van Holsbeke C, Vergote I, et al. Improving strategies for diagnosing ovarian cancer: a summary of the International Ovarian Tumor Analysis (IOTA) studies. *Ultrasound Obstet Gynecol.* 2013;41(1):9-20. doi:10.1002/uog.12323
5. Garg S, Kaur A, Mohi JK, Sibia PK, Kaur N. Evaluation of IOTA simple ultrasound rules to distinguish benign and malignant ovarian tumours. *J Clin Diagn Res.* 2017;11(8):TC06-TC09. doi:10.7860/JCDR/2017/26790.10353
6. Nunes N, Ambler G, Foo X, Naftalin J, Widschwendter M, Jurkovic D. Use of IOTA simple rules for diagnosis of ovarian cancer: meta-analysis. *Ultrasound Obstet Gynecol.* 2014;44(5):503-14. doi:10.1002/uog.13437
7. Yilmaz EP, Kumtepe Y. Endometrial and ovarian cancer with MR imaging: Importance of serum HE4 and CA 125 levels in the extent of disease at evaluation. *Eurasian J Med.* 2016;48(3):192-8. doi: 10.5152/eurasianjmed. 2016.0259



8. Dolgun ZN, Kabaca C, Karateke A, İyibozkurt C, Inan C, Altıntaş AS, et al. The use of human epididymis 4 and cancer antigen 125 tumor markers in the benign or malignant differential diagnosis of pelvic or adnexal masses. *Balkan Med J.* 2017;34(2):156–62. doi:10.4274/balkanmedj.2016.0223
9. Bandiera E, Romani C, Specchia C, Zanotti L, Galli C, Ruggeri G, et al. Serum human epididymis protein 4 and risk for ovarian malignancy algorithm as new diagnostic and prognostic tools for epithelial ovarian cancer management. *Cancer Epidemiol Biomarkers Prev.* 2011;20(12):2496–506. doi:10.1158/1055-9965.EPI-11-0635
10. Kostrzewa M, Zajac A, Wilczyński JR, Stachowiak G. Retrospective analysis of transvaginal ultrasound-guided aspiration of simple ovarian cysts. *Adv Clin Exp Med.* 2019;28(11):1531–5. doi:10.17219/acem/10454
11. Chen H, Qian L, Jiang M, Du Q, Yuan F, Feng W. Performance of IOTA ADNEX model in evaluating adnexal masses in a gynecological oncology center in China. *Ultrasound Obstet Gynecol.* 2019;54(6):815–22. doi:10.1002/uog.20363
12. Nohuz E, De Simone L, Chêne G. Reliability of IOTA score and ADNEX model in the screening of ovarian malignancy in postmenopausal women. *J Gynecol Obstet Hum Reprod.* 2019;48(2):103–7. doi:10.1016/j.jogoh.2018.04.01
13. Landolfo C, Valentin L, Franchi D, Van Holsbeke C, Fruscio R, Froyman W, et al. Differences in ultrasound features of papillations in unilocular-solid adnexal cysts: a retrospective international multicenter study. *Ultrasound Obstet Gynecol.* 2018;52(2):269–78. doi:10.1002/uog.18951
14. Timmerman D, Testa AC, Bourne T, Ameye L, Jurkovic D, Van Holsbeke C, et al. Simple ultrasound-based rules for the diagnosis of ovarian cancer. *Ultrasound Obstet Gynecol.* 2008;31:681–690D.
15. Timmerman D, Ameye L, Fischerova D, Epstein E, Melis GB, Guerriero S, et al. Simple ultrasound rules to distinguish between benign and malignant adnexal masses before surgery: prospective validation by IOTA group. *BMJ.* 2010 Dec 14;341:c6839. doi: 10.1136/bmj.c6839
16. Knafel A, Banas T, Nocun A, Wiechec M, Jach R, Ludwin A, et al: The prospective external validation of International Ovarian Tumor Analysis (IOTA) simple rules in the hands of level I and II examiners. *Ultraschall Med.* 2016 Oct;37(5):516-23. doi: 10.1055/s-0034-1398773
17. Tinnangwattana D, Vichak-urrote L, Tontivuthikul P, Charoenratana C, Lerthiranwong T, Tongsong T. IOTA simple rules in differentiating between benign and malignant adnexal masses by non-expert examiners. *Asian Pac J Cancer Prev.* 2015;16:3835-8.
18. Simmons AR, Baggerly K, Bast RC Jr. The emerging role of HE4 in the evaluation of epithelial ovarian and endometrial carcinomas. *Oncology (Williston Park).* 2013;27(6):548–56.
19. Terlikowska KM, Dobrzycka B, Witkowska AM, Mackowiak-Matejczyk B, Sledziewski TK, Kinalski M, et al. Preoperative HE4, CA125 and ROMA in the differential diagnosis of benign and malignant adnexal masses. *J Ovarian Res.* 2016;9(1):43. doi:10.1186/s13048-016-0254-7
20. Janas L, Głowacka E, Wilczyński JR, Malinowski A, Nowak M. Ocena użyteczności oznaczeń białka HE4 i algorytmu ROMA w przedoperacyjnej diagnostyce guzów przydatków [Evaluation of applicability of HE4 and ROMA in the preoperative diagnosis of adnexal masses]. *Ginekol Pol.* 2015;86(3):193–7. doi:10.17772/gp/2062
21. Piovano E, Cavallero C, Fuso L, Viora E, Ferrero A, Gregori G, et al. Diagnostic accuracy and cost-effectiveness of different strategies to triage women with adnexal masses: a prospective study. *Ultrasound Obstet Gynecol.* 2017;50(3):395–403. doi:10.1002/uog.17320