

CASE REPORT

1. Obstetrics and Gynecology Service, Central Hospital "Dr. Urquinaona", Maracaibo, Zulia State, Venezuela
 - a. Doctor of Clinical Medicine, OB/GYN specialist
 - b. Medical specialist in Gynecology and Obstetrics

Ethics statement

Authorship attribution: All authors declare that they have contributed to the idea, study design, data collection, analysis and interpretation, and critical review of the intellectual content. All authors approved the submitted manuscript.

Ethical responsibilities: Protection of human subjects: The authors declare that the procedures performed were in accordance with the ethical provisions of the corresponding human research ethics committee, as well as the World Medical Association and the Declaration of Helsinki.

Data confidentiality: The authors declare that they have followed the protocols issued by the Central Hospital "Dr. Urquinaona" and by the University of Zulia regarding publication of patients' data.

Right to privacy and informed consent: The authors obtained informed consent from all patients and/or subjects present in the paper. The corresponding author is in possession of these documents.

Funding: The authors certify that they have not received financial support, equipment, work personnel nor objects from people, public and/or private institutions to perform this study.

Conflict of interest: The authors declare they do not have any conflict of interest

Received: May 16, 2019

Accepted: November 1, 2019

Online publication: 8 June 2020

Correspondencia:

Dr. Eduardo Reyna-Villasmil

📍 Hospital Central "Dr. Urquinaona" Final Av. El Milagro, Maracaibo, Estado Zulia, Venezuela

☎ 58162605233

✉ sippenbauch@gmail.com

Cite as: Reyna-Villasmil E, Torres-Cepeda D, Rondon-Tapia M. Rupture of uterine artery pseudoaneurysm after cesarean section. *Rev Peru Ginecol Obstet.* 2020;66(2) DOI: <https://doi.org/10.31403/rpgov66i2255>

Rupture of uterine artery pseudoaneurysm after cesarean section

Rotura de pseudoaneurisma de la arteria uterina posterior a cesárea

Eduardo Reyna-Villasmil^{1,a}, Duly Torres-Cepeda^{1,a}, Martha Rondon-Tapia^{1,b}

DOI: <https://doi.org/10.31403/rpgov66i2255>

ABSTRACT

Postpartum hemorrhage is an important cause of maternal mortality. The rupture of a uterine artery pseudoaneurysm, a rare vascular lesion of unknown prevalence, produces secondary postpartum hemorrhage without an evident cause. If not properly diagnosed and treated, it can be life threatening. Etiology includes vascular trauma during cesarean section, vaginal delivery, curettage or hysterotomy. Its clinical presentation is varied and often associated with other more frequent gynecological and obstetric pathologies. Patients may present no symptoms, vaginal bleeding or even postpartum hemorrhage and hypovolemic shock. To prevent fatal bleeding, a rapid and accurate diagnosis must be made, based on non-invasive imaging studies. Angiographic embolization is a safe and effective method to control hemorrhage in hemodynamically stable patients and should be an option before resorting to surgery in selected cases. We describe a case of rupture of uterine artery pseudoaneurysm following a cesarean section.

Key words: Uterine artery, pseudoaneurysm, Postpartum hemorrhage, Angiography.

RESUMEN

La hemorragia posparto es una causa importante de mortalidad materna. La rotura del pseudoaneurisma de la arteria uterina es una lesión vascular con prevalencia desconocida que produce hemorragia posparto secundaria sin causa evidente. Puede ser potencialmente mortal, si no es diagnosticada y tratada adecuadamente. La etiología incluye traumatismo vascular durante la cesárea, parto vaginal, legrado o histerotomía. Su presentación clínica tiene variedad de síntomas que a menudo se asocian con otras patologías ginecológicas / obstétricas más frecuentes, con y sin sangrado vaginal, y puede abarcar desde ausencia de síntomas hasta hemorragia posparto severa con choque hipovolémico. Para evitar la hemorragia mortal, se debe hacer un diagnóstico rápido y preciso que muestre la naturaleza vascular de esta lesión. El diagnóstico está basado en estudios de imágenes no invasivos. En casos seleccionados adecuadamente, la embolización angiográfica es un método seguro y eficaz para controlar la hemorragia en pacientes hemodinámicamente estables y debe ser una opción antes de recurrir a la cirugía. Se describe un caso de rotura de pseudoaneurisma de arteria uterina posterior a cesárea.

Palabras clave. Arteria uterina, pseudoaneurisma, Hemorragia posparto, Angiografía.

INTRODUCTION

A pseudoaneurysm is a collection of extraluminal blood in an arterial wall defect, contained by the adventitia or by surrounding perivascular soft tissue⁽¹⁾. A uterine artery pseudoaneurysm is a rare complication of unknown prevalence, in which a lacerated wall of the uterine artery presents inadequate sealing. It may manifest as severe hemorrhage in the late post-operative period, depending on size of the lesion and intramural pressure⁽²⁾. It may also be asymptomatic, or cause vaginal bleeding, abdominal pain, hypovolemic shock or fever, if it is infected. It must be considered as a differential diagnosis in cases of late genital bleeding without evident cause and history of gynecologic or obstetric surgery⁽¹⁻⁴⁾. We describe the case of a patient who presented rupture of uterine artery pseudoaneurysm after a C-section.

CASE REPORT

A 26-year-old patient, gravida 3, para 2, with history of previous cesarean section, was admitted for heavy genital bleeding with blood clots that had started in the last 24 hours, accompanied by dizziness, after 5 days

of fever. The patient had undergone a C-section due to breech presentation without complications 16 days before; the newborn weighted 3 200 g and had Apgar scores of 7 and 9 at minute one and five, respectively. On the third day postpartum, the patient had been discharged, asymptomatic. Her pregnancy had been normal and she denied history of coagulation disorders.

At admission, physical examination showed fever (38.3°C), blood pressure of 122/70 mmHg and heart rate of 145 bpm. The patient presented breast swelling; her abdomen was bland, depressible and slightly painful, without bloating nor rigidity. Uterine size resembled that of a 10 weeks' gestation; uterine tone was normal. At vaginal examination, the external os was closed, and there were moderate bright red blood and some clots in vagina. Adnexa mobilization was painless; there were no palpable tumors. White blood cell count was 14 100 cells/mL, neutrophils 85%, platelets 395 000/L and hemoglobin 8,6 g/dl. Liver and renal function tests, coagulation profile and electrolytes were normal. Upon admission, the patient was treated with tranexamic acid, methylergometrine, crystalloids, blood products and antibiotics. To limit bleeding, uterine compression by urinary catheter was applied. Her diagnosis was secondary postpartum hemorrhage.

Abdominopelvic ultrasound showed hypoechoic material inside the uterine cavity consistent with clots; however, in the lower left quadrant of the lower uterine segment, it revealed a small oval anechogenic image measuring 12 x 10 mm close to the endometrial cavity, with a hyperintense border near the zone of hysterorrhaphy, accompanied by a small amount of free intracavitary fluid. Doppler ultrasound evidenced turbulent blood flow inside the lesion (Figure 1). These studies suggested the possible diagnosis of uterine artery pseudoaneurysm, which was confirmed by pelvic CT angiography (Figure 2).

Because of these findings, the persistent bleeding despite pharmacological and mechanical measures, and the potential risks of hysterectomy, it was advised to perform arterial embolization. The patient was transferred to the interventional radiology service, where, by means of a digital subtraction angiography, the internal iliac vessels were removed to reveal an irregular collection of contrast (approximately 2 cm in diameter) inside the pseudoaneurysm, in the dis-

FIGURE 1. COLOR DOPPLER IMAGE OF THE CYSTIC LESION IN UTERUS, MEASURING 12 X 10 MM, WITH TURBULENT FLOW.

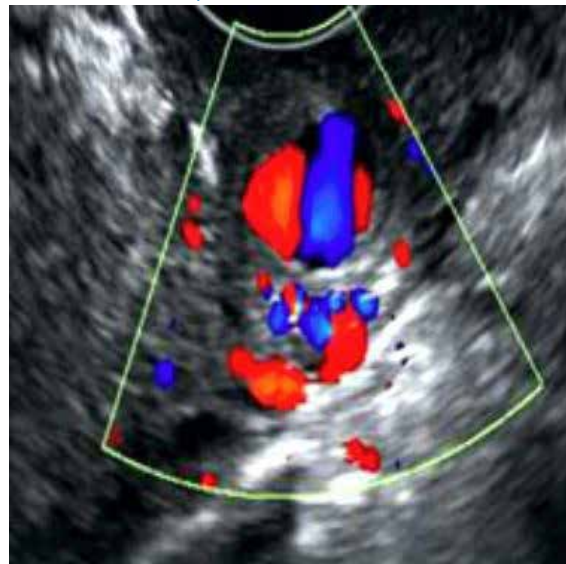
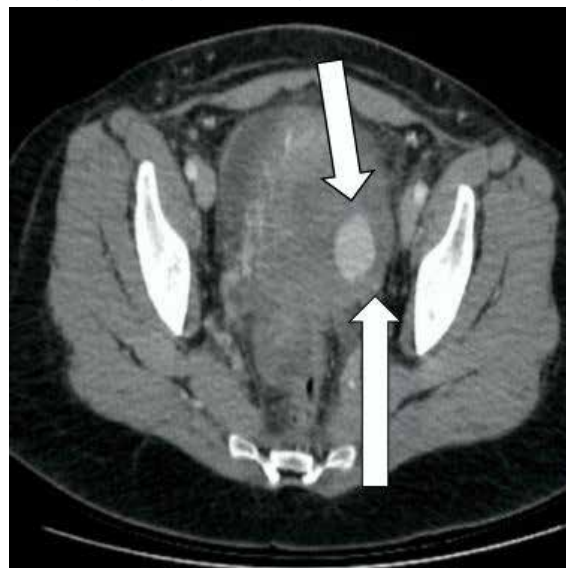


FIGURE 2. CORONAL IMAGE OF CT ANGIOGRAPHY. THE LOWER ARROW POINTS TO THE LEFT UTERINE ARTERY AND THE UPPER ARROW POINTS TO THE PSEUDOANEURYSM OF THE LEFT UTERINE ARTERY.

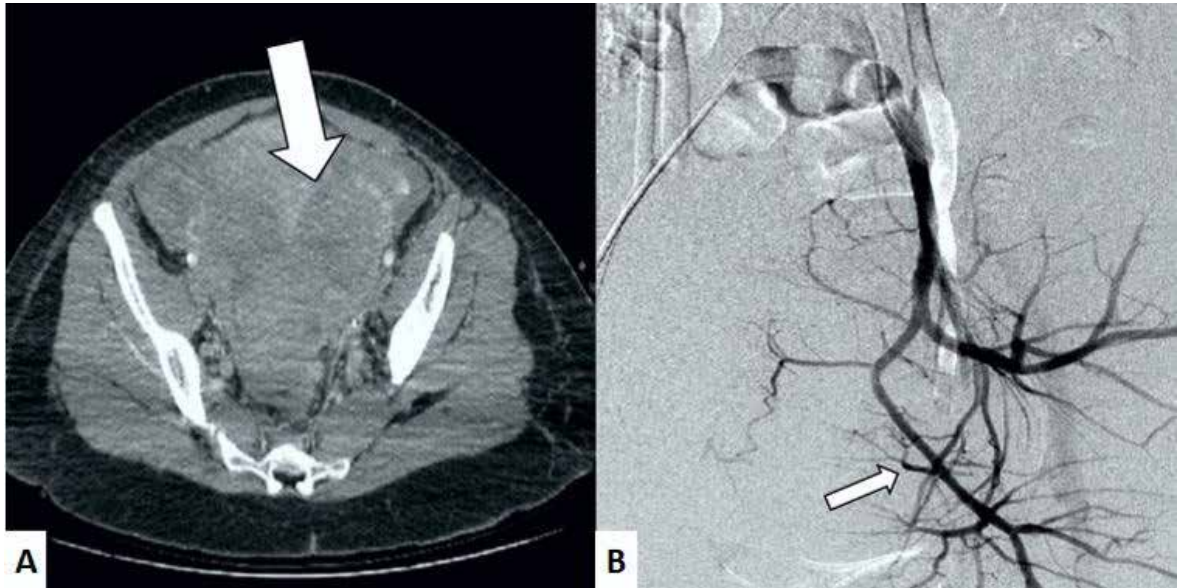


tal end of the left uterine artery. The contrast did not enter the vagina. Selective catheterization of uterine arteries and embolization with a microcatheter were performed, without complications. Genital bleeding decreased significantly. CT angiography and angiogram after treatment showed thrombosis of the pseudoaneurysm, with preservation of the other branches of the internal iliac arteries (Figure 3).

After the embolization, genital bleeding disappeared and the patient said she was feeling well. A follow-up ultrasound showed no pseudoaneurysm.



FIGURE 3. IMAGES AFTER THE EMBOLIZATION. A) CT SCAN; THE ARROW POINTS TO THE THROMBOSED PSEUDOANEURYSM. B) ANGIOGRAPHY; THE ARROW POINTS TO THE OCCLUSION OF THE LEFT UTERINE ARTERY.



White blood cell count returned to normal values by the fifth day post procedure and the patient was discharged after completing antibiotic therapy.

11 days after embolization, the patient returned with a new episode of heavy genital bleeding followed by hypovolemic shock due to intraabdominal hemorrhage. At laparotomy, the anterior uterine surface was densely adhered to the abdominal wall. Because the peritoneal surface was swollen and friable, subtotal abdominal hysterectomy with conservation of both adnexa was performed. The patient was discharged on the fifth postoperative day. After a 16-month follow-up, the patient has not presented complications nor new episodes of genital bleeding.

Pathological examination of the surgical specimen reported a higher number of blood vessels, with thickened vascular walls and hyalinization throughout the myometrium, accompanied by hemorrhage in the basal layer of the endometrium and scarce inflammatory reaction. The uterine artery showed a pouch 15 mm in diameter, with a 5 mm defect in its surface. At microscopy, we found that the pseudoaneurysm wall was composed exclusively of adventitia.

DISCUSSION

Postpartum hemorrhage is an important cause of maternal morbidity and mortality. Secondary postpartum hemorrhage is defined as excessive

bleeding from 24 hours until six weeks after delivery. If the cause is unknown, it can be mortal. Possible etiologies include placental retention, endometritis, subinvolution of the placental bed, uterine artery pseudoaneurysm, arteriovenous malformations and choriocarcinoma^(1,2).

A pseudoaneurysm, also called false aneurysm, is an extravascular blood collection similar to a hematoma, produced outside the arterial wall, characterized by leaking of arterial blood contained by surrounding tissue, which may break and cause severe hemorrhages. Most cases present after gynecologic surgery⁽⁴⁻⁶⁾. The proposed pathophysiological mechanisms for vascular injury are massive artery ligation or puncture wounds when a suture is passed between two vessels. This leads to an expanding periarterial hematoma, vein drainage or both, which would result in a secondary aneurysm or pseudoaneurysm lacking a complete arterial wall with three layers (intima, media, adventitia)⁽⁴⁾. This vascular lesion may occur spontaneously or secondary to inflammation, trauma or local infection⁽⁵⁾.

Clinical manifestations are various, unspecific and unpredictable. It may be asymptomatic or present as a late postpartum or postoperative hemorrhage, and be potentially mortal up to two years after surgery^(3,7). Diagnostic difficulties arise from its unknown frequency and variable presentation of vaginal bleeding. By sustained pressure, blood dissects the tissue around the



damaged artery, creating a perfused pouch. While in contact with the originating vessel, the blood continues dissecting, establishing a connection with the uterine cavity that leads to late hemorrhage, usually massive and unexpected⁽⁸⁾.

Pseudoaneurysms can be identified by ultrasound, CT scan or angiography. Ultrasound and CT scan are used as initial diagnostic techniques. At grayscale ultrasound, this lesion appears as an anechoic cystic lesion, with turbulent arterial flow at Doppler evaluation. Pathognomonic signs have been proposed: the "to-and-fro" waveform in the neck and the "yin-yang sign" in the main body of the pseudoaneurysm. During systole, blood enters because of the higher blood pressure; in diastole, pressure falls and the blood returns through the neck of the pseudoaneurysm⁽⁹⁾. Contrast CT scan may rule out other more frequent causes of secondary postpartum hemorrhage and identify the aneurysm. Besides, CT angiography may show the originating artery. Nevertheless, conventional angiography remains as the gold standard for diagnosing and treating vascular anomalies. The precise diagnosis of secondary postpartum hemorrhage avoids unnecessary interventions, thus limiting blood loss that puts the patient's life at risk⁽¹⁰⁾.

Initial treatment includes volume replacement and blood transfusions, as well as mechanical compression on vagina or uterus. Since rupture is unpredictable, conservative treatment is not a viable option⁽²⁾. If the bleeding persists, treatment options include hysterectomy, surgical ligation or selective embolization of the uterine artery. Embolization, first described in 1979, is useful to control the bleeding; its success rate is circa 97%⁽¹¹⁾. In comparison, success rates for ligation of the internal iliac artery vary from 42% to 100%⁽¹²⁾. Furthermore, embolization has advantages such as less morbidity and the possibility of locating the site of hemorrhage. With this technique, the occlusion can be more distal than with surgical ligation, thus preserving fertility, unlike hysterectomy⁽¹³⁾. Complications are rare because of the abundant vasculature of the pelvis; they include postoperative fever and transitory ischemia (both respond to symptomatic treatment), sciatic and perineal nerves neuropathy, muscle pain and post-embolization syndrome. The procedure has to be practiced bilaterally to ensure its effectiveness and prevent reperfusion⁽¹⁴⁾. Surgery must be performed if embolization has failed⁽¹⁵⁾.

In conclusion, uterine artery pseudoaneurysm is a rare but important cause of secondary postpartum hemorrhage. In cases with history of C-section, this hemorrhage may lead to hypovolemic shock. Uterine artery pseudoaneurysm can be mortal and must be considered as a differential diagnosis. For these cases, angiographic embolization is a treatment option to consider before surgery.

REFERENCES

1. Subramaniam S, Nadarajan C, Aziz ME. Role of uterine artery embolization in pseudoaneurysm of uterine artery: a rare cause of secondary postpartum hemorrhage. *Cureus*. 2018;10(2):e2220. doi: 10.7759/cureus.2220
2. Isono W, Tsutsumi R, Wada-Hiraike O, Fujimoto A, Osuga Y, Yano T, et al. Uterine artery pseudoaneurysm after cesarean section: case report and literature review. *J Minim Invasive Gynecol*. 2010;17(6):687-91. doi: 10.1016/j.jmig.2010.06.004
3. Jennings L, Presley B, Krywko D. Uterine artery pseudoaneurysm: a life-threatening cause of vaginal bleeding in the emergency department. *J Emerg Med*. 2019;56(3):327-31. doi: 10.1016/j.jemermed.2018.12.016
4. Usman R, Jamil M, Rasheed M. True aneurysm of the uterine artery in a young nulliparous female: an extremely rare vascular entity. *Ann Vasc Dis*. 2018;11(4):542-4. doi: 10.3400/avd.cr.18-00066
5. Takeda A, Kato K, Mori M, Sakai K, Mitsui T, Nakamura H. Late massive uterine hemorrhage caused by ruptured uterine artery pseudoaneurysm after laparoscopic-assisted myomectomy. *J Minim Invasive Gynecol*. 2008;15(2):212-6. doi: 10.1016/j.jmig.2007.09.006
6. Feld Z, Rowen T, Callen A, Goldstein R, Poder L. Uterine artery pseudoaneurysm in the setting of deep endometriosis: an uncommon cause of hemoperitoneum in pregnancy. *Emerg Radiol*. 2018;25(1):107-10. doi: 10.1007/s10140-017-1560-0
7. Pérez-Ezquerro BR, Carazo-Hernández B, Arribas-Marco T, Guardia-Dodorico L. Pseudoaneurisma de arteria uterina después de una cesárea. *Ginecol Obstet Mex*. 2013;81(3):166-70.
8. Wan AY, Shin JH, Yoon HK, Ko GY, Park S, Seong NJ, et al. Post-operative hemorrhage after myomectomy: safety and efficacy of transcatheter uterine artery embolization. *Korean J Radiol*. 2014;15(3):356-63. doi: 10.3348/kjr.2014.15.3.356
9. Mahmoud MZ, Al-Saadi M, Abuderman A, Alzimami KS, Alkhorayef M, Almagli B, et al. "To-and-fro" waveform in the diagnosis of arterial pseudoaneurysms. *World J Radiol*. 2015;7(5):89-99. doi: 10.4329/wjr.v7.i5.89
10. Ludwin A, Martins WP, Ludwin I. Managing uterine artery pseudoaneurysm after myomectomy. *Ultrasound Obstet Gynecol*. 2018;52(3):413-5. doi: 10.1002/uog.18963
11. Singhal S, Singh A, Raghunandan C, Gupta U, Dutt S. Uterine artery embolization: exploring new dimensions in obstetric emergencies. *Oman Med J*. 2014;29(3):217-9. doi: 10.5001/omj.2014.53
12. Su CW. Postpartum hemorrhage. *Prim Care*. 2012;39(1):167-87. doi: 10.1016/j.pop.2011.11.009
13. McClucas B, Voorhees WD 3rd, Elliott S. Fertility after uterine



- artery embolization: a review. *Minim Invasive Ther Allied Technol.* 2016;25(1):1-7. doi: 10.3109/13645706.2015.1074082
14. Kaur R, Singh R. Effective management of early cervical pregnancy with bilateral uterine artery embolization followed by immediate evacuation and curettage: A case report. *J Obstet Gynaecol India.* 2017;67(1):66-9. doi: 10.1007/s13224-016-0943-6
 15. Hongsakul K, Songjamrat A, Rookkapan S. Transarterial embolization for the treatment of massive bleeding in gynecologic and obstetric emergencies: a single center experience. *Emerg Radiol.* 2014;21(4):333-9. doi: 10.1007/s10140-014-1198-0

