

# ORIGINAL PAPER

## ARTÍCULO ORIGINAL

1. Gynecologist, Doctor of Medicine, Head of the Department of Gynecology and Obstetrics at the Arzobispo Loayza National Hospital, Lima, Peru; Senior Professor, Cayetano Heredia University, Lima, Peru
2. Gynecologist, Head of the Gynecology Service at the Arzobispo Loayza National Hospital, Lima, Peru
3. Attending physician, Gynecology Service at the Arzobispo Loayza National Hospital, Lima, Peru
4. Extraordinary Professor, Coordinator MEGEMAPE research group, National University of San Marcos, Lima, Peru. ORCID ID: <https://orcid.org/0000-0002-3168-6717>. Scopus author ID: 34971781600

**Funding statement:** The study did not receive any specific funding from any person or entity; it was funded solely by the authors

**Conflicts of interest:** The authors declare that there is no conflict of interest with any statement, institution or person. The collaborating researchers from the hospital have signed the authorship statement regarding the participation of the control group (TOT).

Received: 5 January 2019

Accepted: 3 December 2019

Published online: 5 February 2020

### Correspondence:

Alejandro Siu Au

☎ 999661002

✉ [Alejandro.c.siu@gmail.com](mailto:Alejandro.c.siu@gmail.com)

**Cite:** Siu Au A, Mere del Castillo J, Gutiérrez I, Silva A, Avila R, Pacheco-Romero J. Transobturador suburethral tape versus suburethral tape placement in female stress urinary incontinence. *Rev Peru Ginecol Obstet.* 2020;66(1):31-35. DOI: <https://doi.org/10.31403/rpgo.v66i2229>

# Transobturador suburethral tape versus suburethral tape placement in female stress urinary incontinence

## Cinta suburetral versus cinta transobturatriz en el tratamiento de la incontinencia urinaria de esfuerzo femenina

Alejandro Siu Au<sup>1</sup>, Juan Mere del Castillo<sup>2</sup>, Italo Gutiérrez<sup>3</sup>, Arnaldo Silva<sup>3</sup>, Roberto Avila<sup>3</sup>, José Pacheco-Romero<sup>4</sup>

DOI: <https://doi.org/10.31403/rpgo.v66i2229>

### ABSTRACT

**Introduction:** The surgical management of stress urinary incontinence uses the transobturador tape (TOT) technique since 2006. We present a study applying the suburethral tape as a better alternative that does not require the TOT needle. **Objective:** To demonstrate the advantages of the suburethral tape placement technique over the transobturador tape technique in the surgical treatment of stress urinary incontinence. **Methods:** Observational comparative study using the non-invasive suburethral tape placement versus the transobturador tape technique. **Results:** Fifty patients were treated with TOT for stress urinary incontinence and other 50 patients were managed with suburethral tape placement (UTP) in the previous shift the same day or the preceding day. The TOT patients were 56 years old on average, and time of the procedure was 18 minutes on average. Complications included pain in the inguinal area (13 cases), mesh extrusion (2 cases), and suture dehiscence of anterior colporrhaphy, presence of left inguinoperineal granuloma due to mesh reaction and bruising in the left obturator area (one case of each). The 50 patients treated with UTP were 56 years old on average, operating time was 7 minutes on average, and there were no complications. The cost of the TOT kit was about US\$ 1 000.00, and the suburethral tape cost was US\$ 50.00. **Conclusions:** In this study of stress urinary incontinence treatment, the suburethral tape technique was safer than the transobturador tape technique and had a lower cost.

**Key words:** Urinary Incontinence, Stress, Suburethral Slings, Transobturador Suburethral Tape, Urethral Sling.

### RESUMEN

**Introducción.** Entre los tratamientos quirúrgicos de la incontinencia urinaria de esfuerzo se emplea la técnica de la cinta transobturatriz (TOT, por sus siglas en inglés) desde el 2006 hasta la actualidad. Se presenta un estudio con la aplicación de la cinta uretral (UTP, por sus siglas en inglés) como mejor alternativa al no usar la aguja del TOT. **Objetivo.** Demostrar las ventajas de la aplicación de la cinta suburetral versus la cinta transobturatriz en el tratamiento quirúrgico de la incontinencia urinaria de esfuerzo. **Métodos.** Estudio observacional, comparativo con la técnica no invasiva empleando cinta suburetral versus la técnica de la cinta transobturatriz. **Resultados.** Se evaluó 50 pacientes intervenidas con TOT, quienes precedieron un turno el mismo día o el día precedente a las pacientes operadas con la cinta uretral. El promedio de edad fue 56 años y el tiempo promedio del procedimiento fue 18 minutos. Las complicaciones consistieron en dolor en la zona inguinal (13 casos), extrusión de malla (2 casos) y, una de cada caso, dehiscencia de sutura de la colporrafia anterior, presencia de granuloma inguinoperineal izquierdo por reacción a la malla, hematoma en zona obturatriz izquierda. En los 50 casos tratados con cinta suburetral, el promedio de edad fue 56 años, el tiempo operatorio 7 minutos y no existió complicación alguna. El costo del kit de la TOT fue alrededor de US\$ 1 000.00; la cinta suburetral costó US\$ 50.00. **Conclusiones.** En la presente serie de manejo de la incontinencia urinaria de esfuerzo, la técnica de la cinta suburetral resultó más segura que la técnica de la cinta transobturatriz y fue de menor costo. **Palabras clave.** Incontinencia urinaria, esfuerzo, Cinta Quirúrgica, uretral.



## INTRODUCTION

The revolution in the surgical management of female stress urinary incontinence began with Ulmstein's report in Europe, 1966, about the tension free vaginal tape technique – TVT, which consisted in placing a sling by the blind passage of a needle through the retropubic space<sup>(6,7)</sup>. At the end of the 1990s, this became the most frequently performed procedure in the world, with over 500 000 surgeries of this kind and healing rates at 1, 3, 5 and 7 years of 91%, 86%, 87% and 81,3%, respectively<sup>(1-5)</sup>.

In France, 2001, Delome presented a variant for this procedure, the transobturator tape – TOT, which consists in placing a suburethral tape through the obturator foramen in the pelvis<sup>(8)</sup>. Ever since, this procedure has been performed thousands of times throughout the world<sup>(9-14)</sup>.

The TOT technique's advantages include its simplicity and low complication rates. It avoids abdominal incisions and passing a needle into the retropubic space, thus decreasing the risk of serious injuries of the bladder, intestine, blood vessels and nerves, rendering the routine use of intraoperative cystoscopy unnecessary<sup>(13-16)</sup>.

In March 2006, our department decided to apply the TOT technique in patients presenting with stress urinary incontinence who accepted the procedure. Throughout this time, technique-inherent complications have emerged, so the main author (ASA) proposed avoiding passage of needles through the obturator foramina and cutting the mesh to obtain a smaller tape that would lead to a milder foreign body reaction<sup>(17-19)</sup>, that is to say, the suburethral tape placing technique (UTP).

We are aware that the American Food and Drug Administration banned the commercialization of mesh for use in pelvic organ prolapse on US territory by a press release on April 16, 2019. However, it only addresses mesh for repairing the anterior compartment (cystocele) and the posterior compartment (rectocele), without mentioning the sling for the treatment of stress urinary incontinence. Thus, we consider that the technique we present here remains valid.

## METHODS

We performed an observational comparative study between the UTP and the TOT techniques, where the patients selected for TOT were those operated on the previous shift the same day or the day before the patients operated with the UTP. The study began in January 2012 and patient recruitment stopped in June 2017. Follow-up continued until June 2018, with at least one year of follow-up time per patient.

One hundred patients were recruited and randomized to undergo voluntarily one of the surgical techniques. All patients had a surgical indication for stress urinary incontinence diagnosed via cystometric study with stress test or computer-based, and all accepted to participate and signed the informed consent.

We excluded patients diagnosed with urge incontinence or mixed urinary incontinence, with an incomplete preoperative workup, or with contraindications to surgery, as well as patients who did not accept the procedure or had doubts, or who did not sign the informed consent.

The postoperative assessment after discharge was performed two to four weeks after the procedure, with a one-year follow-up consisting in at least two appointments.

Surgical material included a full TOT kit, which consisted in needles for the transobturator passage and a Marlex mesh for the urethra, made of polypropylene or prolene to reduce costs. We obtained four to five tapes out of each Marlex mesh (Figure 1).

Regarding surgical technique, the techniques of TOT and UTP are based on stabilizing the middle area of the urethra by placing a sling. Both techniques were performed after vaginal hysterectomy, if it was required, and/or before finishing the corresponding colpoperineorrhaphy. The TOT technique has been described extensively in the literature<sup>(8-14,18)</sup>.

In the case of UTP, the needle does not pass through the obturator foramen. The pubovesical cervical fascia has to be dissected with the finger, until the obturator foramen is reached and the pubic symphysis is touched (Figure 2). The





FIGURE 1. CUTTING THE MESH TO OBTAIN A SLING IN THE SUBURETHRAL TAPE PLACEMENT (UTP) TECHNIQUE.

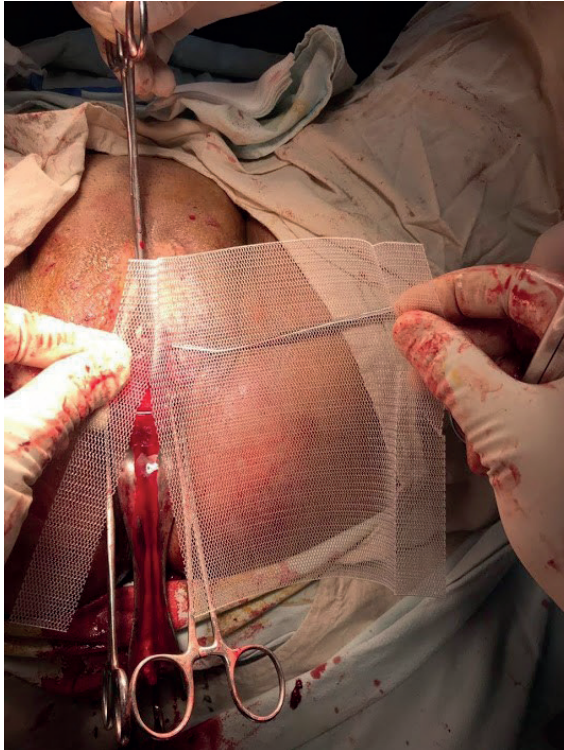


FIGURE 2. INTRODUCING THE INDEX FINGER TO DISSECT THE TISSUE UNTIL IT REACHES THE PUBIC SYMPHYSIS, BILATERALLY. THERE ARE NO INGUINAL INCISIONS.

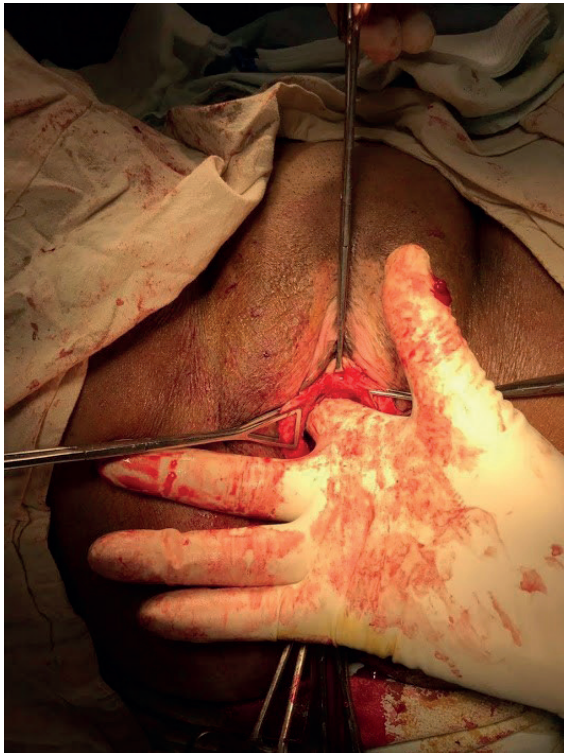


FIGURE 3. THE TAPE IS CARRIED FORWARD WITH A DISSECTING FORCEPS UNTIL IT REACHES THE OBTURATOR AREA.

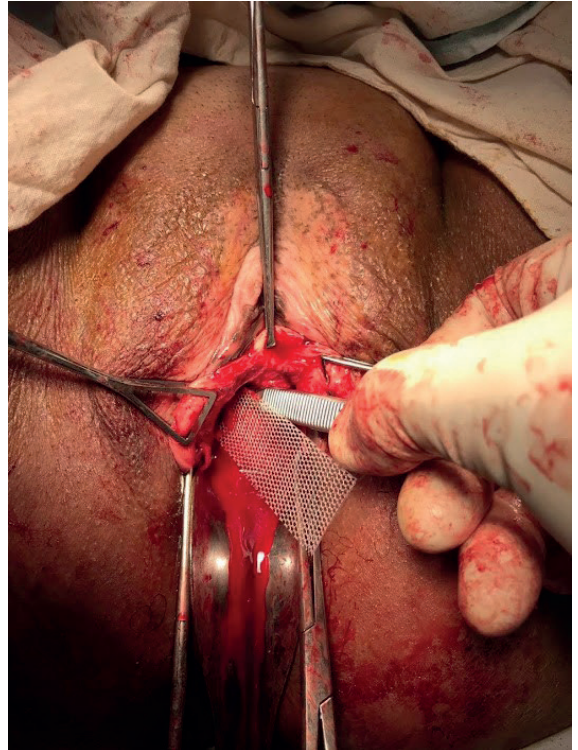
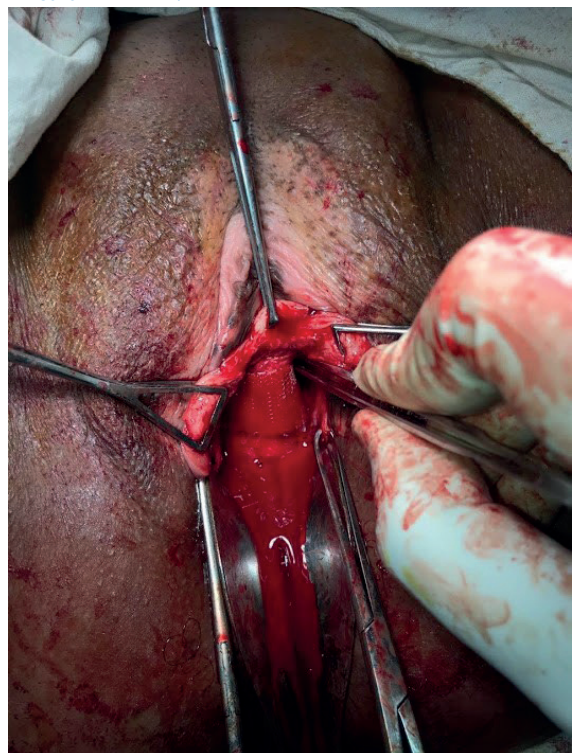


FIGURE 4. THE SAME IS DONE ON THE OTHER SIDE. IF IT IS TOO LONG, CUT THE SUBURETHRAL TAPE.





tape is presented, cut and installed with a clamp, after having approximated its position with the finger or the clamp (Figure 3). The same procedure is done on the other side (Figure 4).

Postoperative management was similar in both techniques. The urinary catheter was retired the day following surgery, coupled with analgesics and antibiotics if required, and the patient was encouraged to walk.

## RESULTS

The average age of all patients was 56 years old, and the average parity was five pregnancies (Table 1). Of the 50 TOT patients, 45 also underwent vaginal hysterectomy and anteroposterior colpoperineorrhaphy, and five had only an anteroposterior colpoperineorrhaphy. Of the 50 UTP patients, 42 also underwent vaginal hysterectomy and anteroposterior colpoperineorrhaphy, and eight had only an anteroposterior colpoperineorrhaphy.

Average time for completion of the TOT technique was 18 minutes and for UTP, 7 minutes (see table).

TABLE 1. PATIENT CHARACTERISTICS, SURGICAL PROCEDURES AND COMPLICATIONS WITH THE TRANSOBTURATOR TECHNIQUE (TOT) AND THE SUBURETHRAL TAPE TECHNIQUE (UTP)

Characteristics	TOT	UTP
Number of patients	50	50
Average age in years	56	56
Average parity	5	5
Vaginal hysterectomy and anterior colpoperineorrhaphy	45	46
Anterior colpoperineorrhaphy	6	2
Average operating time in minutes	18	7
<b>Complications inherent to the technique</b>		
Pain in the groin area due to Emmet needle puncture	13	0
Mesh extrusion	2	0
Dehiscence of anterior colpoperineorrhaphy with mesh extrusion	1	0
Hematoma in left obturator foramen	1	0
<b>Complications unrelated to the technique</b>		
Urinary tract infection	28	24
Vault hematoma post vaginal hysterectomy	6	5
Urinary retention after catheter removal	4	2
Vault infection post vaginal hysterectomy	4	4
Hepatic encephalopathy	1	0
Pneumonia	1	0

Complications inherent to the TOT technique were pain in the inguinal area due to Emmet needle puncture, mesh extrusion, wound dehiscence of anterior colpoperineorrhaphy with mesh exposition and bruising in the left obturator foramen.

There were no complications inherent to the UTP technique (Table 1).

Complications unrelated to the TOT technique were urinary tract infection, vault hematoma after vaginal hysterectomy, urinary retention after removal of urethral catheter (one patient had the catheter replaced once), vault infection after vaginal hysterectomy, hepatic encephalopathy and pneumonia.

Complications unrelated to the UTP technique were urinary tract infection, vault hematoma after vaginal hysterectomy, vault infection after vaginal hysterectomy and urinary retention after removal urethral catheter (Table 1).

Until June 2019, the patients' evolution and follow-ups did not reveal recurrent stress urinary incontinence.

## DISCUSSION

We have not found any bibliographic reference describing the suburethral tape placement technique, in our search for comparing it to the TOT technique.

In our study, most patients operated with TOT and UTP had a favorable evolution and early ambulation after surgery. Both groups had similar age, parity, and underwent similar vaginal procedures. However, we observed that the operating time of UTP is shorter than that of TOT: 7 minutes versus 18 minutes, respectively.

Regarding inherent complications of the TOT technique, we observed pain in the needle puncture area, mesh extrusion or rejection, and suture dehiscence – both maybe due to foreign body reaction – and local bruising. On the other hand, we did not observe any foreign body complications with the UTP technique. This could be due to the shorter and smaller sling it uses, with a smaller area than in TOT.





The TOT kit costs approximately \$1000. Meanwhile, the value of the suburethral tape is approximately \$50 and it is sufficient for four slings for four procedures; this means, each sling has a value of \$13.

Regarding complications unrelated to the techniques, there were no significant differences.

Finally, we observe that both techniques were effective in the treatment of stress urinary incontinence.

The study's limitations are that it took place in a public hospital that lacks material resources, and that some patients from both techniques were lost to follow-up because they did not come to their postoperative controls.

We conclude that, in our series, the suburethral tape was better than the TOT because it had a shorter operating time, it had less complications, and it was less expensive.

## REFERENCES

1. Ulmsten U, Petros P. Intravaginal slingplasty (IVS): An ambulatory surgical procedure for treatment of female urinary incontinence. *Scand J Urol Nephrol.* 1995 Mar;29(1):75-82. DOI: 10.1007/bf01902378
2. Petros P, Ulmsten U. An integral theory of female urinary incontinence. Experimental and clinical considerations. *Acta Obstet Gynecol Scand Suppl.* 1990;153:7-31. DOI: 10.1016/j.juro.2008.09.002
3. Ulmsten U, Jonson P, Rezapour M. A three-year follow up of tension free vaginal tape for surgical treatment of female stress urinary incontinence. *Br J Obstet Gynaecol.* 1999 Apr;106(4):345-50. DOI: 10.1111/j.1471-0528.1999.tb08272.x
4. Haab F, Sananes S, Amarenco G, Ciofu C, Uzan S, Gattegno B, Thibault P. Results of the tension-free vaginal tape procedure for the treatment of type II stress urinary incontinence at a minimum follow up of a 1 year. *J Urol.* 2001 Jan;165(1):159-62. DOI: 10.1097/00005392-200101000-00038
5. Balmforth J, Cardozo L. Trends toward less invasive treatment of female stress urinary incontinence. *Urology.* 2003 Oct; 62(4 Suppl 1):52-60. DOI: 10.1016/s0090-4295(03)00677-0
6. DeLancey JO. Structural support of the urethra as it relates to stress urinary incontinence: the hammock hypothesis. *Am J Obstet Gynecol* 1994 Jun;170(6):1713-20. DOI: 10.1016/s0002-9378(94)70346-9
7. Walters MD, Tulikangas PK, LaSala C, Muir TW. Vascular injury during tension-free vaginal tape procedure for stress urinary incontinence. *Obstet Gynecol.* 2001 Nov;98(5 Pt 2):957-9. DOI: 10.1016/s0029-7844(01)01560-5
8. Delorme E. La bandelette trans-obturatrice: un procédé mini-invasif pour traiter l'incontinence urinaire d'effort de la femme. *Prog Urol.* 2001 Dec;11(6):1306-13.
9. Dargent D, Bretones S, George P. Pose d'un ruban sous urétral oblique par voie obturatrice dans le traitement de l'incontinence urinaire féminine. *Gynécologie Obstétrique Fertil.* 2002 Jul-Aug;30(7-8):576-82.
10. Mellier G, Benayed B, Bretones S, Pasquier JC. Suburethral tape via the obturator route: is the TOT a simplification of the TVT? *Int Urogynecol J Pelvic Floor Dysfunct.* 2004 Jul-Aug;15(4):227-32. DOI: 10.1007/s00192-004-1162-8
11. Delorme E, Droupy S, Delmas V. Transobturator tape (Ura-tape): a new minimally-invasive procedure to treat female urinary incontinence. *Eur Urol.* 2004 Feb;45(2):203-7. DOI: 10.1016/j.eururo.2003.12.001
12. Faúndez E, González E. Cinta vaginal libre de tensión en el tratamiento de la incontinencia de orina femenina. una nueva forma de inserción: a través del agujero obturador (CLT-AO). *Rev Chil Obstet Ginecol.* 2003;68(5):355-60.
13. Roa J, Roa E, Romero G. Experiencia con swing sub uretral libre de tensión transobturator (TOT) en el tratamiento de la incontinencia urinaria femenina. *Rev Chil Obstet Ginecol.* 2004;69(4):294-300.
14. Briozzo L, Vidiella G, Curbelo F, Craviotto F, Massena B, Varela López R y col. Transvaginal obturatriz tape (TOT) en el tratamiento de la incontinencia urinaria de esfuerzo femenina. *Rev Med Uruguay.* 2005;21:130-40.
15. Whiteside JL, Walters MD. Anatomy of the obturator region: relations to a trans-obturator sling. *Int Urogynecol J Pelvic Floor Dysfunct.* 2004 Jul-Aug;15(4):223-6. DOI: 10.1007/s00192-004-1143-y
16. Victor W, Nitti MD. Complicaciones de los slings miduretrales y su manejo. *Can Urol Assoc J.* 2012 Oct;6(5 Suppl 2):52. <https://doi.org/105489/cuaj.1462>.
17. Siu A, Arteaga L, Bautista M, Burga I. Técnica de colocación de un sling sub-uretral a través de los agujeros obturatrizes (TOT) para el tratamiento de la incontinencia urinaria de esfuerzo femenina. *Rev Viernes Méd.* Julio 2007;32:26-31.
18. Reategui R. Sling transobturatriz-vaginal (TOT). Nueva alternativa mínimamente invasiva en el tratamiento de la incontinencia urinaria de esfuerzo. *Rev Per Urol.* Jul-Dic 2004;14:120-3.