

# SIMPOSIO EMERGENCIAS Y COMPLICACIONES SEVERAS OBSTÉTRICAS

<sup>1</sup> Department of Obstetrics & Gynecology,  
Division of Maternal-Fetal Medicine,  
Medical University of South Carolina,  
Charleston, South Carolina, USA

Conflicts of Interest: None.

Received: August 20, 2016  
Accepted: September 30, 2016

Correspondence:  
Ryan D. Cuff, MD

✉ Cuff@musc.edu

## AMNIOTIC FLUID EMBOLISM: HISTORICAL PERSPECTIVE, PATHOPHYSIOLOGY AND CLINICAL MANAGEMENT

Ryan D. Cuff, MD<sup>1</sup>

### ABSTRACT

Amniotic fluid embolism (hereafter, AFE) is a uniformly devastating event that is both unpredictable and unpreventable. Despite having been first described nearly 80 years ago, it remains a significant cause of maternal mortality worldwide. AFE is characterized by the triad of sudden hypoxia and hypotension, followed in most cases by coagulopathy. The diagnosis of AFE is clinical and prompt recognition and multi-disciplinary intervention essential. This paper seeks to review the history, pathophysiology, potential risk factors, strategies for identification and management, and outcomes of this unfortunate and storied obstetric emergency.

**Keywords:** Amniotic Fluid Embolism; Obstetric Emergency; Disseminated Intravascular Coagulation; Anaphylactoid Syndrome of Pregnancy; Systemic Inflammatory Response Syndrome; Critical Care in Pregnancy.

### EMBOLIA DE LÍQUIDO AMNIÓTICO: PERSPECTIVA HISTÓRICA, FISIOPATOLOGÍA Y MANEJO

#### CLÍNICO

#### RESUMEN

La embolia de líquido amniótico (ELA) es una ocurrencia devastadora, impredecible y no prevenible. A pesar de haber sido descrita por primera vez hace casi 80 años, todavía es causa significativa de mortalidad materna en el mundo. La ELA se caracteriza por la triada consistente en hipoxia súbita e hipotensión, seguida en la mayoría de casos por coagulopatía. El diagnóstico de la ELA es clínico, y es esencial su pronto reconocimiento y la intervención multidisciplinaria. Este artículo trata de revisar la historia, fisiopatología, factores de riesgo potenciales, estrategias para su identificación y manejo, así como los resultados de esta desafortunada y antigua emergencia obstétrica.

**Palabras clave:** Líquido Amniótico, Embolia; Emergencia Obstétrica; Coagulación Intravascular Diseminada; Síndrome Anafilactoide del Embarazo; Síndrome de Respuesta Inflamatoria Sistémica; Cuidados Críticos en la Gestación.



## INTRODUCTION

Amniotic fluid embolism (hereafter, AFE) is a uniformly devastating event that is both unpredictable and unpreventable. Despite having been first described nearly 80 years ago, it remains a significant cause of maternal mortality worldwide<sup>(1-2)</sup>. AFE is characterized by the triad of sudden hypoxia and hypotension, followed in most cases by coagulopathy<sup>(2)</sup>. The diagnosis of AFE is clinical and prompt recognition and multi-disciplinary intervention essential. This paper seeks to review the history, pathophysiology, potential risk factors, strategies for identification and management, and outcomes of this unfortunate and storied obstetric emergency.

## HISTORY

The history of AFE is as fascinating as it is informative, with our present understanding of the disease owing much to its historical roots. Steiner and Lushbaugh coined the term amniotic fluid embolism in 1941 when they reported eight cases of 'maternal pulmonary embolism by amniotic fluid' based on the histopathologic findings at autopsy of components from the fetal compartment in the maternal pulmonary circulation. Such components included: meconium mucous, leukocytes, and squamous cells<sup>(1)</sup>. From Steiner and Lushbaugh's description and initial studies, a relatively simple model of the pathophysiology was developed and involved embolism of amniotic fluid and associated components into the maternal circulation with subsequent obstruction of the pulmonary vasculature and pulmonary arterial blood flow causing hypoxia, heart failure and, ultimately, maternal death<sup>(3)</sup>.

The basis of this pathophysiologic mechanism is rooted in the assumption that neither amniotic fluid, nor its components, escape into the maternal circulation during normal parturition – except in those cases which have yielded a diagnosis of amniotic fluid embolism. This assumption was seemingly confirmed by Sparr and Pritchard in 1958 following an inability to detect the presence of radioactively-labeled red blood cells in the maternal circulation following delivery. The cells had been tagged with chromium and injected into the amniotic cavity. From this, they concluded: "...the finding of any amniotic fluid debris in the maternal lungs is evidence of a pathologic process rather than merely an aftermath of normal labor and delivery."<sup>(4)</sup>

Animal studies seeking to confirm this mechanism yielded markedly conflicting results, with the injection of either autologous or heterologous amniotic fluid into the circulation of various animal models producing a wide array of adverse effects, up to and including sudden death of the animal<sup>(5)</sup>. Of interest, only two studies were carried out in primates and both demonstrated that the intravenous injection of amniotic fluid was entirely benign, without effect on monitored hemodynamic or respiratory parameters<sup>(6-7)</sup>.

In the 1980s, the previously-held pathophysiologic basis of disease was further refuted by several studies that (1) demonstrated the presence of once-presumed etiologic squamous cells in the pulmonary arterial circulation of universally all pregnant patients and (2) described similar clinical presentations and outcomes in patients with conditions unrelated to AFE<sup>(8)</sup>. These findings called into question the long-held assumption about the mechanisms of disease and have led to notable advances in our present understanding of the disease and its management.

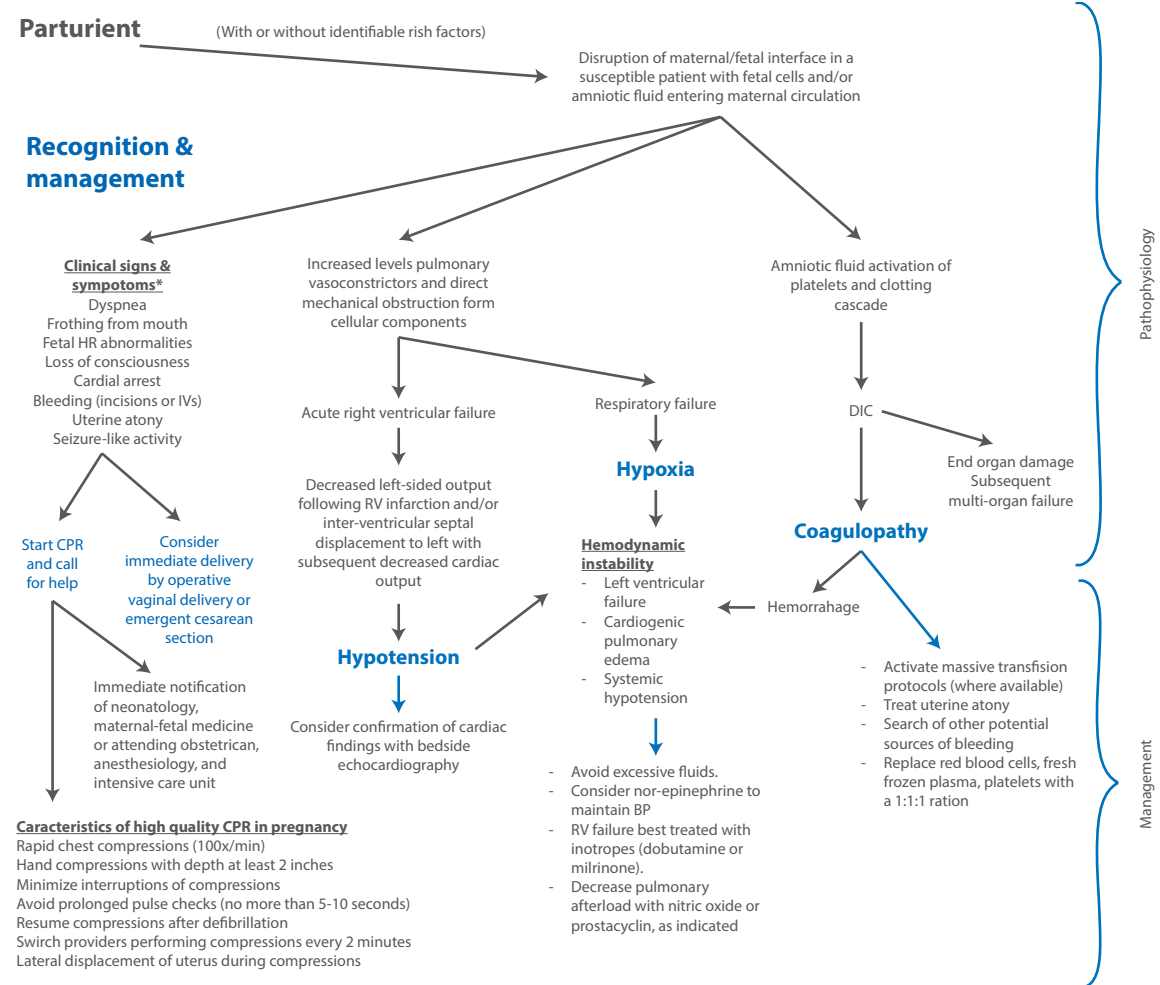
## PATHOPHYSIOLOGY & RISK FACTORS

Our present understanding of the pathophysiology of AFE is not entirely different from that proposed in generations past. Essentially, mechanism seems to hinge on the entrance of materials from the fetal compartment into the maternal circulation that, in a rare minority of parturients, provoke an anaphylactoid-like response that culminates in a clinical picture resembling the systemic inflammatory response syndrome (SIRS) (Figure 1)<sup>(5)</sup>. The clinical triad of hypoxemia, hypotension, and coagulopathy, though non-specific, remains the hallmark of AFE. As such, AFE must be considered in the differential diagnosis for any pregnant or recently postpartum patient who presents with these clinical findings.

AFE has been documented at the time of both vaginal and cesarean deliveries, as well as in case reports following amniocentesis and termination of pregnancy<sup>(10)</sup>. Abenhaim, et al. (2008) evaluated the incidence and risk factors of AFE over the course of 4 years from 1999 – 2003, encompassing nearly 3 million births in the United States. Their study determined the incidence to be 7.7 per 100 000 deliveries, with a case fatality rate of nearly 22%. They concluded that AFE is a rare but serious entity that appeared to be



FIGURE 1. PATHOPHYSIOLOGY & CLINICAL RESPONSE TO SUSPECTED AFE.



Adapted from: SMFM Amniotic fluid embolism: diagnosis and management. Am J Obstet Gynecol 2016.  
 \* Adapted from: Clark Amniotic fluid embolism. Obstet & Gynecol 2008, 123(2)337-48.

associated with abnormal placentation – specifically placenta previa and abruptio placentae, advanced maternal age, and cesarean delivery<sup>(11)</sup>. Their study did not find, as some have suggested in the past, an association of medical induction of labor with risk for AFE<sup>(12)</sup>.

Concerningly, current trends in obstetrics mirror the independently-associated risk factors for AFE, with increasing maternal age and a trend towards a greater percentage of operative or cesarean deliveries, which predispose patients to placental problems in subsequent pregnancies. As a result, the practicing obstetrician must be aware of AFE and understand not only the pathophysiology but the multidisciplinary management necessary in the acute setting to prevent maternal death. The remainder of this document seeks to provide the practicing clinician with a guide for recognition and management of AFE.

## CLINICAL FEATURES

The classic triad of AFE is hypotension, hypoxemia, and coagulopathy. Prevention of severe maternal and/or fetal morbidity or mortality requires prompt recognition and multi-disciplinary intervention (Figure 1). Analysis of the national registry by Clark, et al. (1995) found that 70% of AFE occur during labor, 11% immediately following vaginal delivery and 19% at time of cesarean delivery<sup>(9)</sup>.

Case reports have demonstrated the patients may have sudden-onset anxiety, mental status changes, anxiety, or sense of impending doom immediately preceding objective clinical findings in AFE<sup>(13)</sup>. Clinically, AFE may present with dyspnea, frothing from the mouth, cyanosis, or bleeding from incision or intravenous sites. Fetal monitoring will present with loss of variability,



decelerations, and terminal bradycardia<sup>(2)</sup>. These findings are the result of oxygen being shunted away from the uterus in the acute phase of the event. Tocometric monitoring may reveal uterine tachysystole in the moments immediately before cardiovascular collapse<sup>(3)</sup>.

## MANAGEMENT

Obstetric providers must be aware of AFE as a clinical entity such that it can be recognized early and also so those caring for parturients know how to respond in order to best minimize obstetric and neonatal morbidity and mortality. A patient suspected of having an AFE needs to be evaluated by an obstetric care provider immediately. Maternal and fetal clinical status should be quickly assessed. Clinical signs and symptoms consistent with potential AFE should prompt a series of overlapping events (Figure 1), starting with concurrent initiation of maternal cardio-pulmonary resuscitation (CPR) and recruitment of needed help.

Simultaneously, neonatal and anesthesia care providers should be notified along with maternal-fetal medicine subspecialists and intensive care providers. Furthermore, obstetric care providers should assess the patient's labor course and make preparations for either expeditious operative vaginal delivery or emergent cesarean delivery for the un-delivered patient with a viable fetus.

With regard to CPR, the Figure 1 details the basic components of what has been termed 'high quality CPR in pregnancy.'<sup>(14)</sup> Importantly, preparations for the delivery of the viable fetus must be made simultaneously with initiation of CPR. Viability is determined by estimated gestational age at which neonatal resuscitation is possible. If an operative vaginal delivery by vacuum or forceps is not possible, plans must be made for perimortem emergent cesarean delivery. Emergent cesarean delivery should be embarked upon after four minutes of CPR fails to establish spontaneous circulation<sup>(2)</sup>. Delivery of the viable fetus may assist resuscitative efforts by removal of compression on the vena cava. However, cesarean delivery or laceration at time of operative vaginal delivery may worsen associated coagulopathy.

In addition to CPR and fetal assessment, care providers must also be cognizant of means necessary to address associated right and left-sided

cardiac failure, subsequent hemodynamic instability, and the likely ensuing coagulopathy. With particular respect to cardiac function, increased levels of pulmonary vasoconstrictors, as well as potential mechanical obstruction of pulmonary vasculature from fetal cellular debris may initially cause acute right ventricular failure and respiratory failure with acute hypoxemia. This is characteristic of the first phase of hemodynamic changes associated with AFE. Bedside echocardiogram may confirm these findings, but is not necessary. The second phase of hemodynamic changes is related to left-sided heart failure which ensues following right ventricular infarction. With left-sided failure comes hemodynamic instability, manifest as decreased cardiac output and systemic hypotension. Excessive fluid administration should be avoided. Instead, right ventricular failure should be treated with inotropes, such as dobutamine or milrinone. Inhalational nitric oxide may be administered to decrease pulmonary afterload. Left ventricular failure and systemic hypotension should be treated with norepinephrine<sup>(2)</sup>.

Coagulopathy (Figure 1) arises after the amniotic fluid activation of platelets and clotting cascade produces a consumptive coagulopathy leading to disseminated intravascular coagulation, which ultimately leads to end-organ damage and subsequent multi-organ failure. Furthermore, hemorrhage is common in AFE with bleeding from incision and/or laceration sites or intravenous access sites. Uterine atony is common and should be aggressively managed. The clinician must also search for and treat sources of bleeding that are not related to DIC, such as uterine rupture or vaginal laceration as they will contribute to ongoing coagulopathy. Treating clinicians should activate their local variant of the massive transfusion protocol, replacing red blood cells, fresh frozen plasma, and platelets in a 1:1:1 ratio<sup>(2)</sup>.

## CONCLUSIONS

AFE as a disease has had a storied history. We now know that amniotic fluid or fetal debris in the maternal circulation is neither sufficient to provoke clinical phenotype nor is it diagnostic. AFE is both rare and lethal. It is a true obstetric emergency. Risk factors for AFE, including advanced maternal age, cesarean delivery, or placental problems are all rising in incidence in the general obstetric population and may lead to an



increase in the incidence of AFE. As a result, all clinicians providing care to the parturient must be aware of AFE as a clinical entity and have basic knowledge of how to immediately recognize and promptly intervene to the benefit of the expectant and her fetus.

## REFERENCES

- Steiner PE, Lushbaugh CC. Maternal pulmonary embolism by amniotic fluid. *JAMA*. 1941;117:1245-54.
- Society for Maternal-Fetal Medicine (2016). Amniotic fluid embolism: Diagnosis and management. SMFM Clinical Guideline No.9. *Am J Obstet Gynecol*. 2016 Aug; 215(2):B16-24. DOI: 10.1016/j.ajog.2016.03.012.
- Clark SL. Amniotic fluid embolism. *Obstet Gynecol*. 2014;123(2):337-48. DOI: 10.1097/AOG.000000000000107.
- Sparr RA, Pritchard JA. Studies to detect the escape of amniotic fluid into the maternal circulation during parturition. *Surg Gynecol Obstet*. 1958;107:560-4.
- Dildy GA, Belfort MA, Clark SL. Anaphylactoid syndrome of pregnancy (amniotic fluid embolism). In: Belfort M, Saade G, Foley M, Phelan J, Dildy GA, editors. *Critical care obstetrics*. 5th edition. Oxford (UK):Wiley-Blackwell; 2010:466-74.
- Stolte L, van Kessel H, Steelen J, Eskes T, Wagatsuma T. Failure to produce the syndrome of amniotic fluid embolism by infusion of amniotic fluid and meconium into monkeys. *Am J Obstet Gynecol*. 1967;98:694-7.
- Adamsons K, Mueller-Heubach E, Myer RE. The innocuousness of amniotic fluid infusion in the pregnant rhesus monkey. *Am J Obstet Gynecol*. 1971;109:977-84.
- Clark SL, Pavlova Z, Horenstein J, Phelan JP. Squamous cells in the maternal pulmonary circulation. *Am J Obstet Gynecol*. 1986;154:104-6.
- Clark SL, Hankins GD, Dudley DA, Dildy GA, Porter TF. Amniotic fluid embolism: analysis of the national registry. *Am J Obstet Gynecol*. 1995;172:1158-67.
- Cromey MG, Taylor PJ, Cumming DC. Probably amniotic fluid embolism after first-trimester pregnancy termination: a case report. *J Reprod Med*. 1983;28:209-11.
- Abenhaim HA, Azoulay L, Kramer MS, Leduc L. Incidence and risk factors of amniotic fluid embolisms: a population-based study on 3 million births in the United States. *Am J Obstet Gynecol*. 2008;199:49.e1-8. DOI:10.1016/j.ajog.2007.11.061.
- Kramer MS, Rouleau J, Baskett TF, Joseph KS; Maternal Health Study Group of the Canadian Perinatal Surveillance. Amniotic fluid embolism and medical induction of labour: a retrospective, population-based cohort study. *Lancet*. 2006;368:1444-8. DOI:10.1016/S0140-6736(06)69607-4.
- Ecker JL, Solt K, Fitzsimons MG, MacGillivray TE. Case reports of the Massachusetts General Hospital. Case 40-2012. A 43-year old woman with cardiorespiratory arrest after a cesarean section. *N Engl J Med*. 2012;367:2528-36. DOI:10.1056/NEJMcp1201413.
- Jeejeebhoy FM, Zelop CM, Lipman S, et al; American Heart Association Emergency Cardiovascular Care Committee, Council on Cardiopulmonary, Critical Care, Perioperative and Resuscitation, Council on Cardiovascular Diseases in the Young, and Council on Clinical Cardiology. Cardiac arrest in pregnancy: a scientific statement from the American Heart Association. *Circulation* 2015;132:1747-73. DOI:10.1161/CIR.0000000000000300.

